C3 Glomerulopathy: role of complement for pathogenesis and treatment

Marina Vivarelli

Division of Nephrology and Dialysis
Bambino Gesù Children's Hospital, IRCCS
Rome, Italy

Bambino Gesù
OSPEDALE PEDIATRICO

MPGN: the old classification…

MPGN Type I
Subendothelial deposits
West et al, J Pediatr 1965

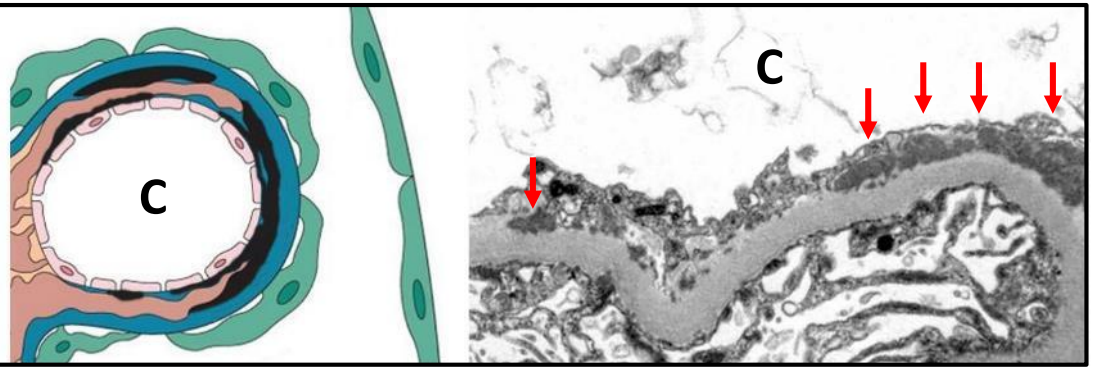

MPGN Type II / DDD
Intramembranous deposits
Galle, Thesis 1962; Habib et al, Kidney Int 1975

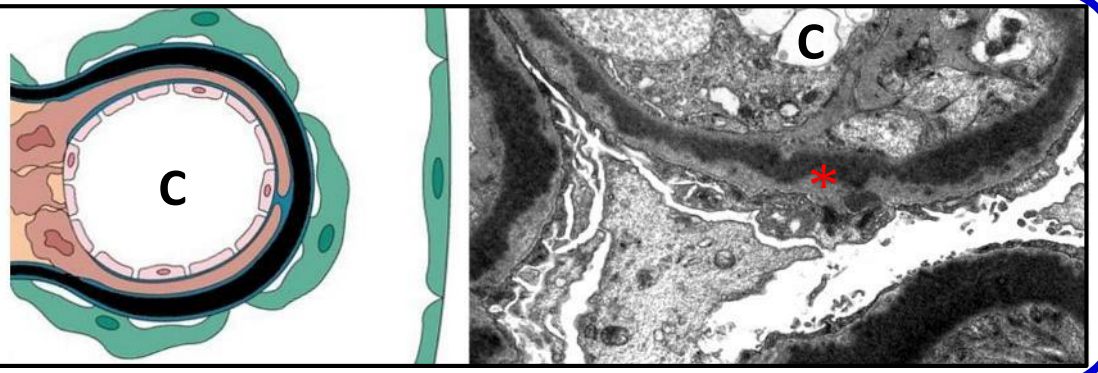

MPGN Type III
Subendothelial and subepithelial deposits
Burkholder et al, Am J Pathol 1969
Anders et al, Virchows Arch A Pathol Anat Histol 1997
Strife et al, Clin Nephrol 1984

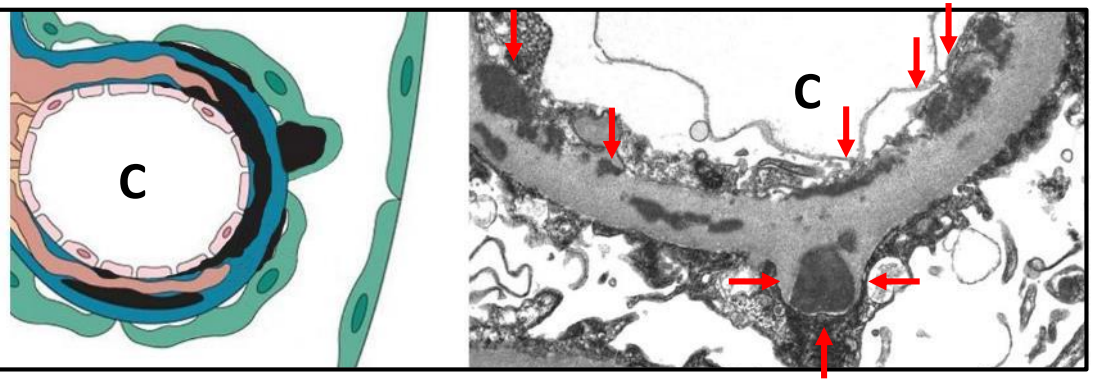

A new disease entity: C3GN

ORIGINAL ARTICLE

Primary glomerulonephritis with isolated C3 deposits: a new entity which shares common genetic risk factors with haemolytic uraemic syndrome

Aude Servais, Véronique Frémeaux-Bacchi, Moglie Lequintrec, Rémi Salomon, Jacques Blouin, Bertrand Knebelmann, Jean-Pierre Grünfeld, Philippe Lesavre, Laure-Hélène Noël, Fadi Fakhouri

J Med Genet 2007;**44**:193–199. doi: 10.1136/jmg.2006.045328

19 patients with unusual glomerulonephritis and:

- C3NeF positivity (7), CFH (3), CFI (2) or MCP (1) mutations

- overt mesangial and epimembranous C3 deposits

- absence of dense intramembranous deposits (no DDD)

- no Ig deposition

→ C3GN

Complement AP dysregulation in kidney diseases

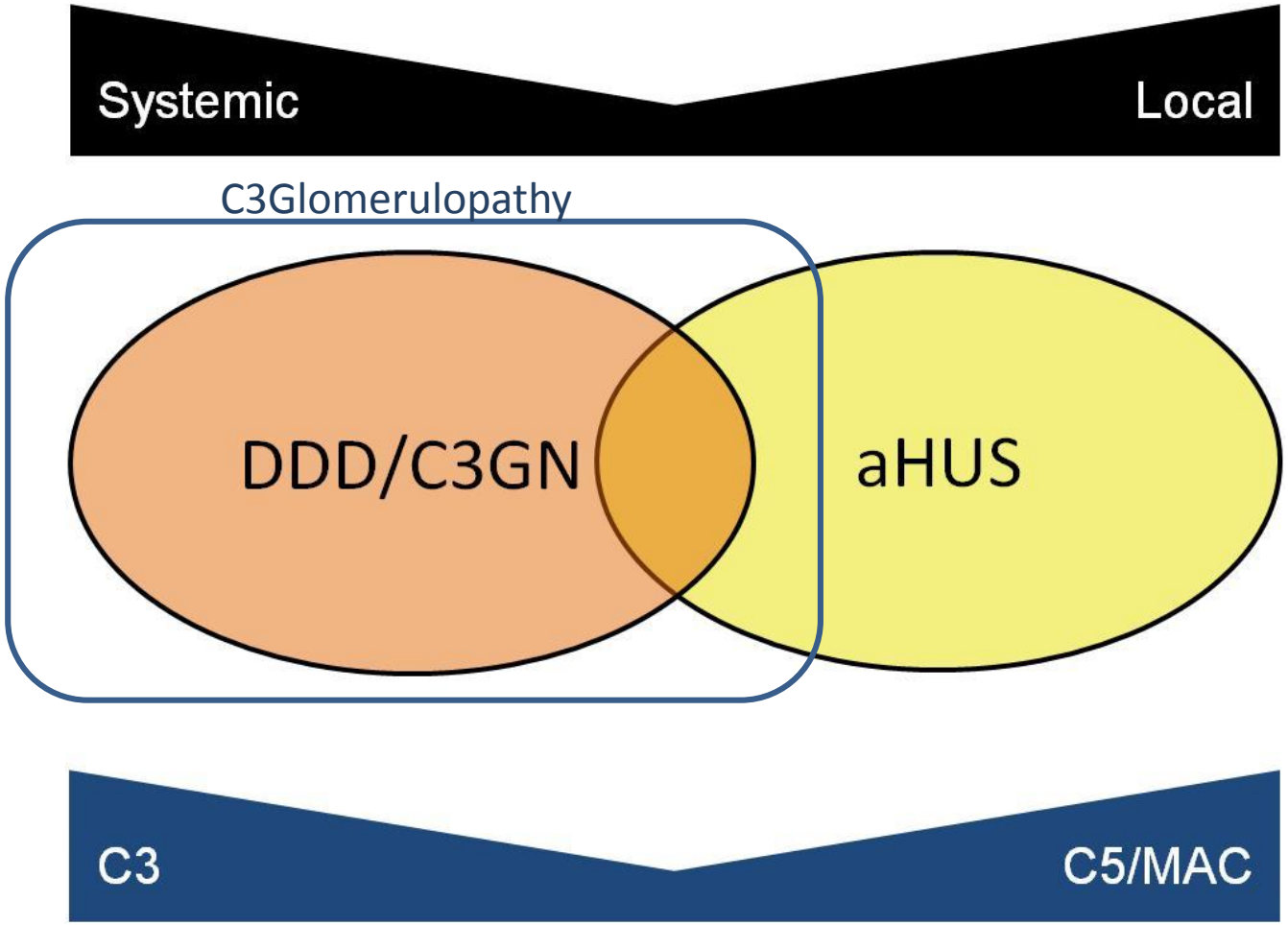

Renal biopsy in C3G

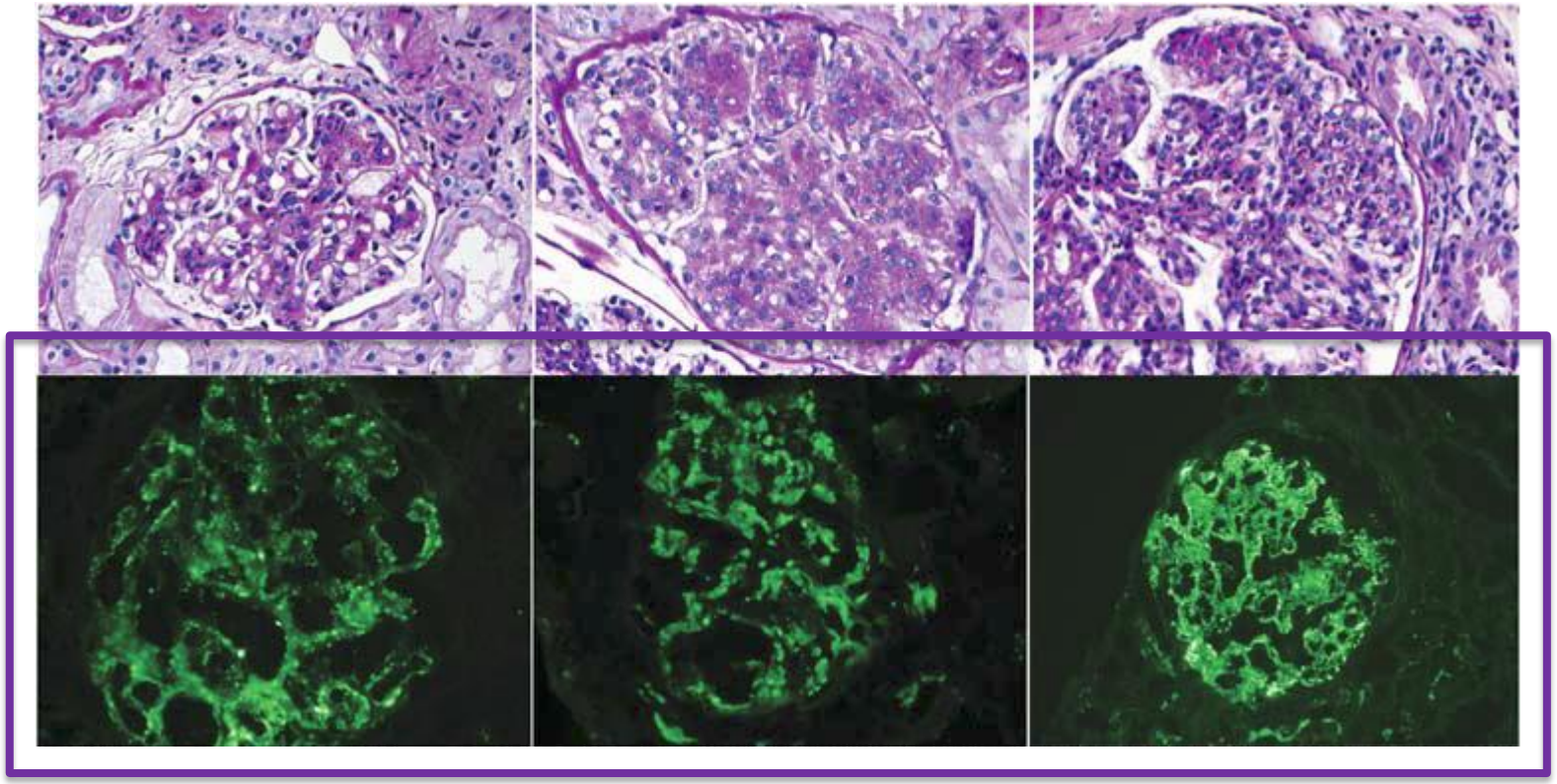

Pickering et al, KI 2013: C3 at least 2-fold brighter than other IF

Sethi S, Kidney International (2012) 82, 465–473

The distinction C3GN/DDD requires electron microscopy

DDD

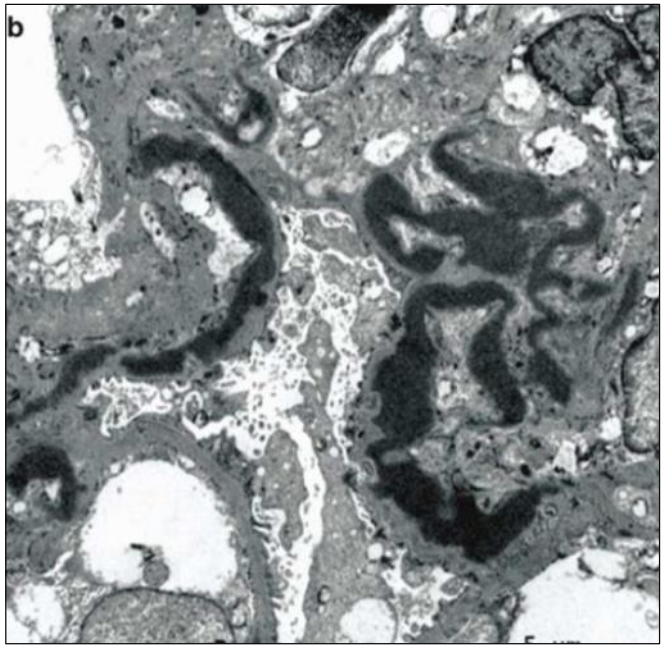

Walker PD et al, Modern Pathol 2007

C3GN

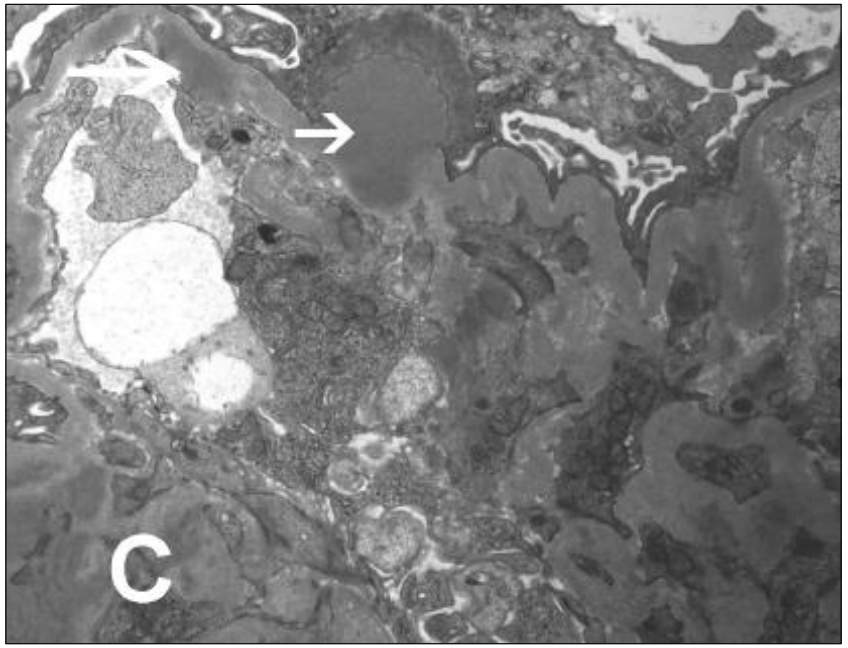

Sethi S et al, Clin J Am Soc Nephrol 2011

Evidence for a role of complement in DDD/C3GN in humans

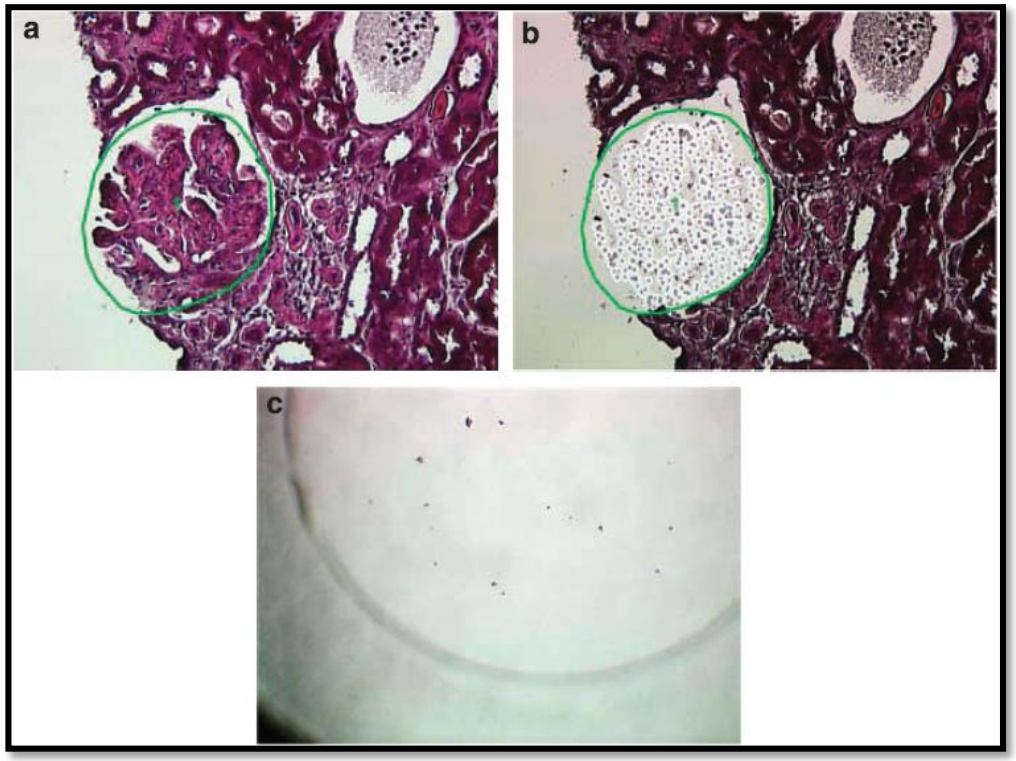

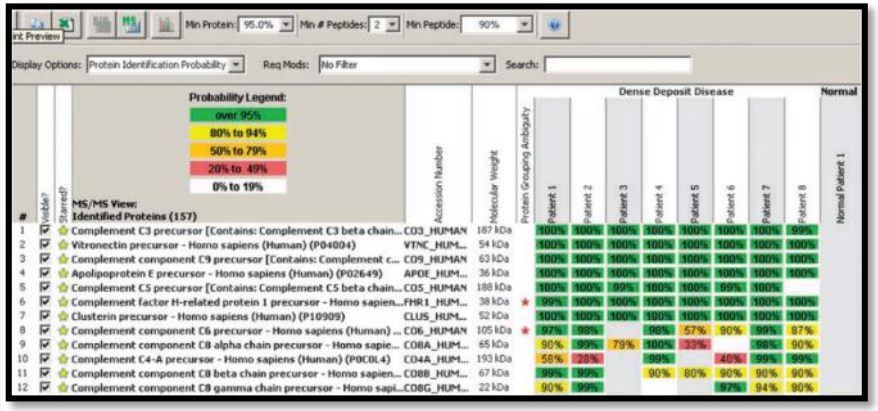

- **Proteomic profile of microdissected glomeruli:**
  C3, C4, C5, C6, C7, C8, CFHR1, CFHR5….
- **Very similar profile between DDD and C3GN**

Sethi et al Kidney Int 2009; Sethi S et al Clin J Am Soc Nephrol 2011

A simplified view of the complement system

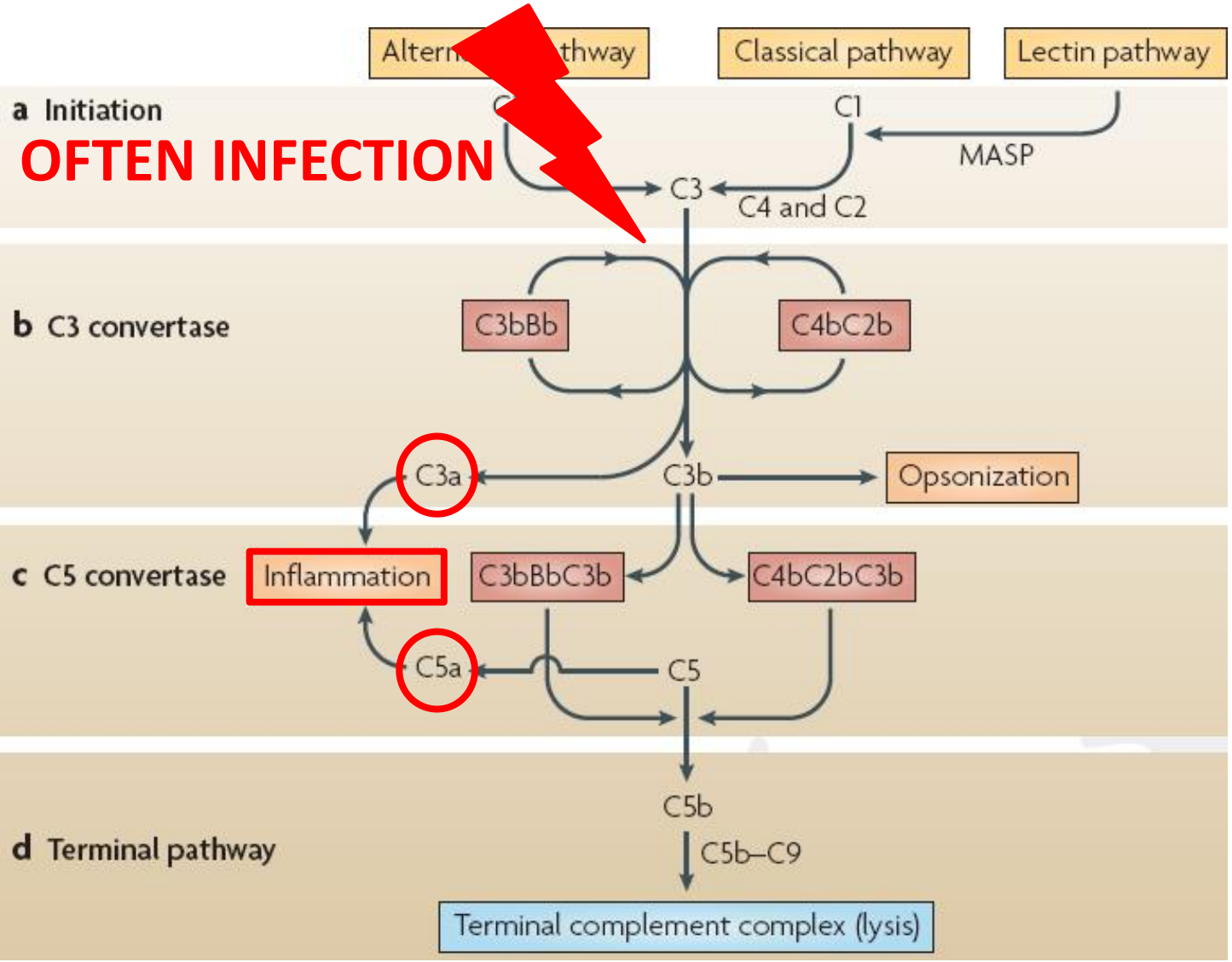

Zipfel and Skerka, Nat Rev Immunol 2009

Different alternative pathway alterations lead to C3 glomerulopathies

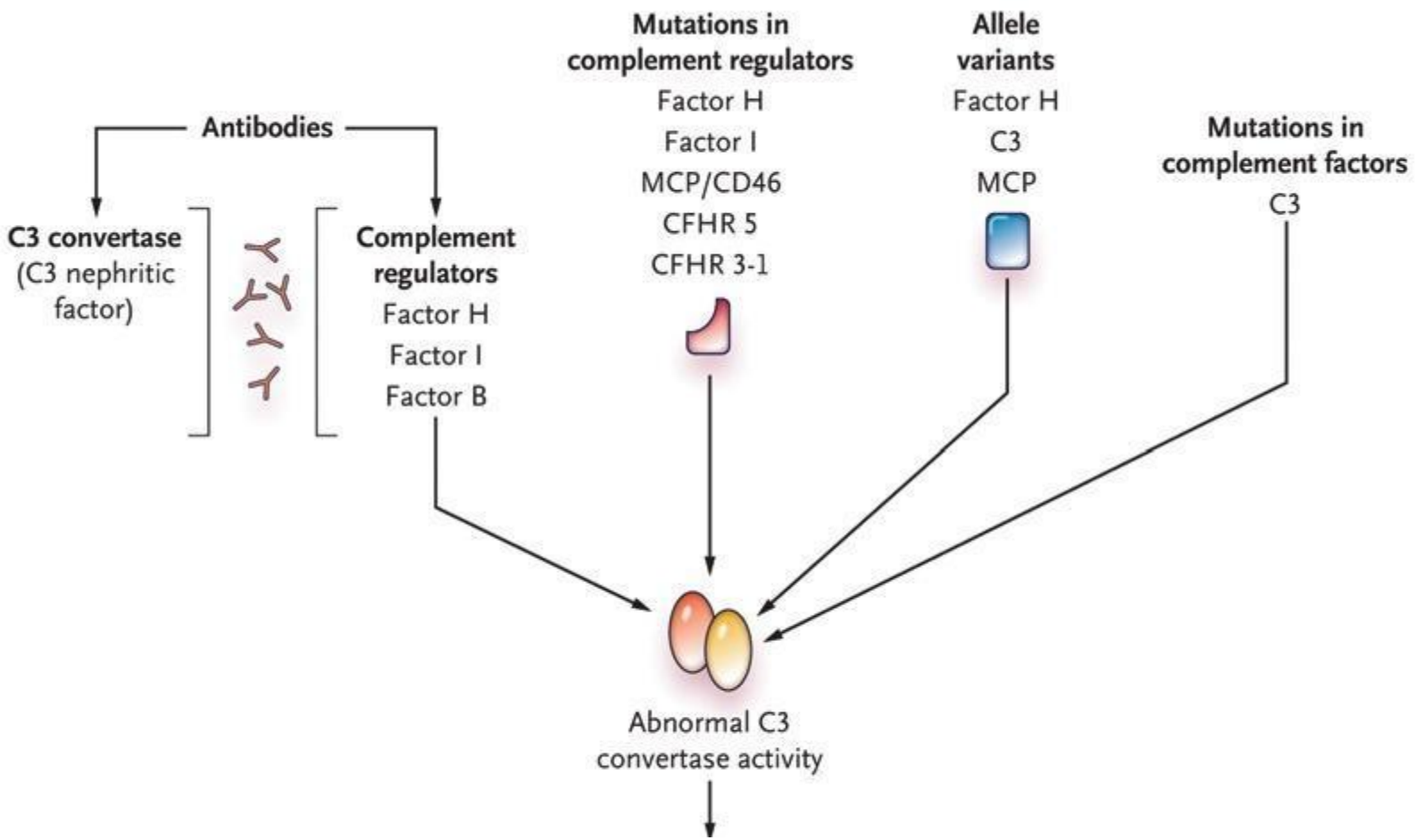

C3 glomerulopathies

modified from Sethi S, Fervenza FC NEJM 2012

New classification of MPGN

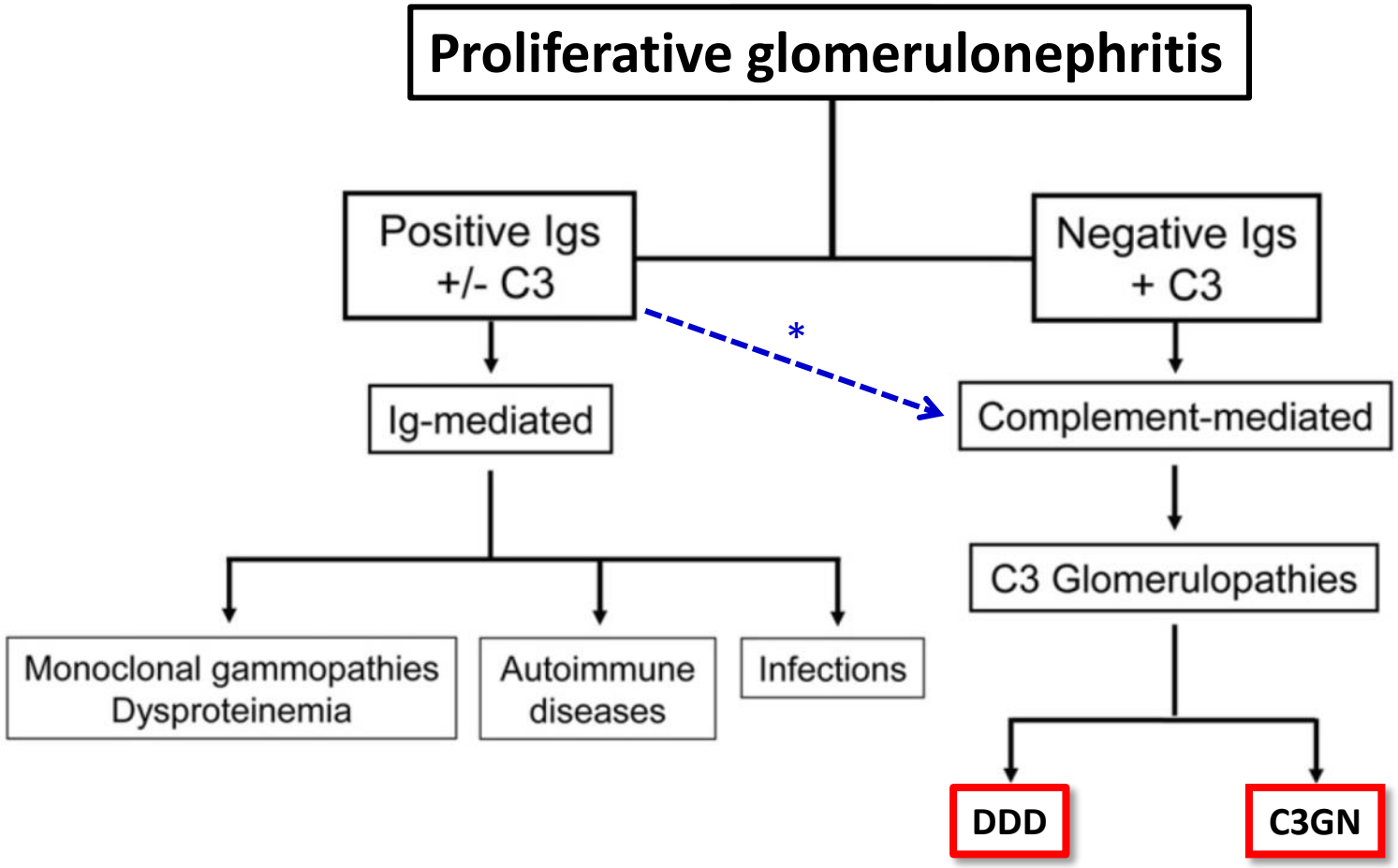

Sethi S and Fervenza FC, Semin Nephrol 2011
Sethi S and Fervenza FC, NEJM 2012

*Servais et al, Kidney Int 2012; Dragon-Durey et al. JASN 2004;
Vaziri-Sani et al. Kidney Int 2006; Leroy V et al. Ped Nephrol 2011

IC-MPGN can also be secondary to dysregulation of the complement alternative pathway: C3Nef

Table 3 | Complement component analysis and immunofluorescence study of membranoproliferative glomerulonephritis type I cases with positive C3 nephritic factor

Patient	C3[a] (660 to 1250 mg/l)	C4[a] (90 to 380 mg/l)	CFB[a] (90 to 320 mg/l)	Histology	Immunofluorescence study
25	537[b]	160	83	MPGN I	IgG, IgM, C3
26	512	127	50	MPGN I	IgG, IgM, IgA, C3
27	183	178	225	MPGN I	IgG, C3
28	701	233	96	MPGN I	IgG, C3
29	87	202	51	MPGN I	IgG, IgM, C3
30	847	222	71	MPGN I	IgG, IgM, C3, C1q
31	48	126	89	MPGN I	IgG, IgA, C3
32	87	309	92	MPGN I	IgG, IgM, C3
33	293	209	100	MPGN I	IgG, IgM, C3
34	180	248	123	MPGN I	IgG, IgM, C3
35	193	95	126	MPGN I	IgG, C3
36	275	225	159	MPGN I	IgG, IgM, C3, C1q
37	1110	162	186	MPGN I	ND[c]
38	475	175	155	MPGN I	IgG, IgA, C3
39	741	169	82	MPGN I	IgG, C3
40	875	273	124	MPGN I	IgG, C3, C1q
41	135	182	130	MPGN I	IgG, IgA, IgM, C3
42	129	227	64	MPGN I	IgG, C3

Abbreviations: CFB, complement factor B; Ig, immunoglobulin; MPGN I, membranoproliferative glomerulonephritis type I; ND, not done.
[a]Laboratory reference values are indicated in brackets.
[b]Rare variant CFI *IVS 12+5* associated.
[c]Biopsy performed in 1974: lobular MPGN I, no immunofluorescence study available.
Cases with genetic abnormality are presented in Table 2.

Servais et al, Kidney Int 2012

IC-MPGN can also be secondary to dysregulation of the complement alternative pathway: genetic mutations

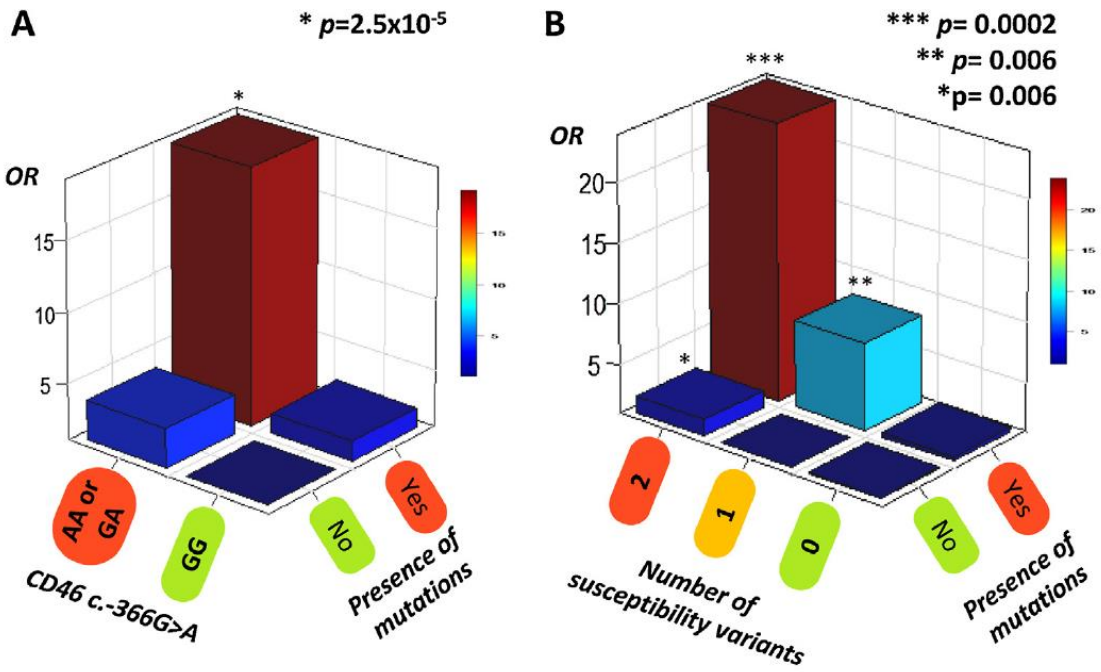

Ig-MPGN

Mutation/s	SVs	Pt	Ctr
Yes	1	15.6%	2.1%
Yes	0	1.6%	1.0%
No	1	76.6%	80.8%
No	0	6.3%	16.1%

C3G

Mutation/s	SVs	Pt	Ctr
Yes	2	9.9%	0.7%
Yes	1	8.5%	1.7%
Yes	0	0.0%	0.7%
No	2	47.9%	35.3%
No	1	25.4%	47.2%
No	0	8.5%	14.3%

Iatropoulos et al, Mol Immunol 2016

IC-MPGN can also be secondary to dysregulation of the complement alternative pathway: anti-FB and anti-C3b

Anti-Factor B and Anti-C3b Autoantibodies in C3 Glomerulopathy and Ig-Associated Membranoproliferative GN

Maria Chiara Marinozzi,*† Lubka T. Roumenina,*‡§ Sophie Chauvet,* Alexandre Hertig,‖ Dominique Bertrand,¶ Jérome Olagne,** Marie Frimat,†† Tim Ulinski,‡‡ Georges Deschênes,§§ Stephane Burtey,‖‖ Michel Delahousse,¶¶ Bruno Moulin,** Christophe Legendre,*** Véronique Frémeaux-Bacchi,*† and Moglie Le Quintrec*¶¶

Table 1. Summary of the clinical characteristics of the pat

Pt	Sex	Age at Onset, yr	Background	Ig-MPGN/C3G	Infectious Trigger
1	M	31	Drug/HBV	Ig-MPGN	Yes
2	F	34	Anorexia	Ig-MPGN	Yes
3	F	66		C3G	No
4	M	40	Myelofibrosis	Ig-MPGN	Yes
5	M	49		Ig-MPGN	No
6	M	32		C3G	No
7	M	7		C3G	Yes
8	M	63	Alcohol/HBV	Ig-MPGN/C3G	Yes
9	F	9		C3G	No
10	M	55		Ig-MPGN	Yes
11	M	34		Ig-MPGN	Na
12	M	38	Drug	Ig-MPGN	Yes
13	M	55	Crohn/B lymphoma	Ig-MPGN	Yes
14	F	32		Ig-MPGN	Na
15	M	18		C3G	Na

The CKD stages are defined by the level of kidney function according to the Kidne
1.73 m^2; stage 3, GFR between 30 and 59 ml/min per 1.73 m^2; stage 4, GFR betwee
Pt, patient; NS, nephrotic syndrome; IS, immunosuppressive treatment; M, male;

Marinozzi et al, JASN 2017

The value of repeat biopsies

First biopsy

Second biopsy

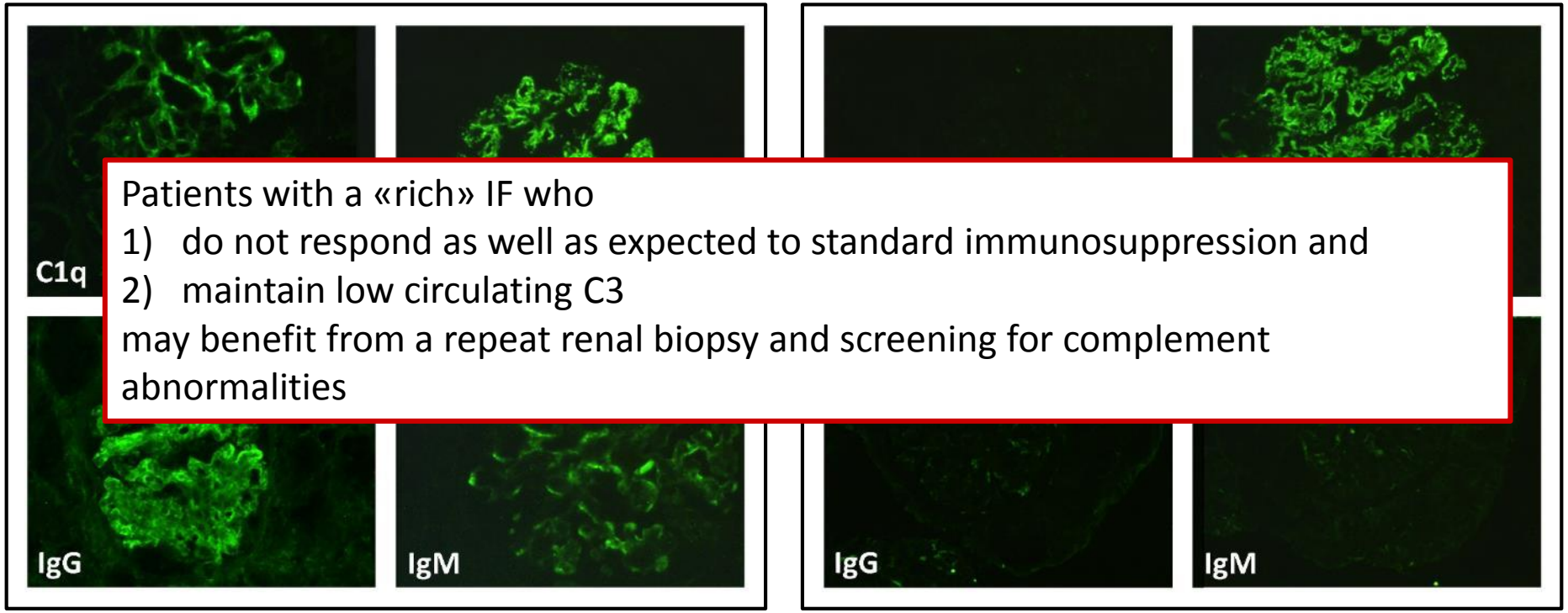

Patients with a «rich» IF who

1) do not respond as well as expected to standard immunosuppression and
2) maintain low circulating C3

may benefit from a repeat renal biopsy and screening for complement abnormalities

Positive C3Nef
Elevated C5b9
MCP mutation

What can we learn from the renal biopsy?

C4d as a Diagnostic Tool in Proliferative GN

Sanjeev Sethi,* Samih H Nasr,* An S. De Vriese,† and Fernando C. Fervenza‡

J Am Soc Nephrol 26: ●●●–●●●, 2015

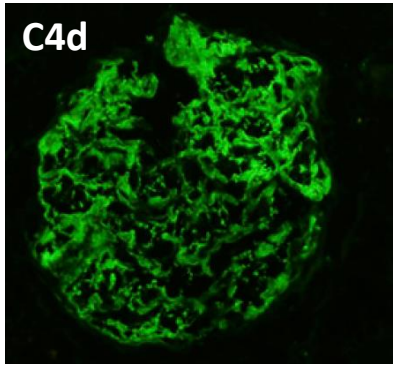

Proliferative glomerulonephritis

Immune-complex mediated GN

Ig ++/+++
C3 +/++/+++

- C1q +/++/+++, C4d+/++/+++ → CP activation
  - Eg: Autoimmune disease, monoclonal Ig, infections*
- C1q 0/trace, C4d ++/+++ → LP activation
  - Eg: Infections, IgA nephropathy, membranous nephropathy, monoclonal Ig**

Complement-mediated GN

C3 ++/+++
Ig 0/+

- C1q 0/trace/1+, C4d +/++/+++ → LP/CP activation, possibly in addition to AP
  - Eg: C3 glomerulopathy triggered by infections, autoimmune disease, monoclonal Ig****
- C1q 0, C4d 0/trace → AP activation
  - Eg: C3 glomerulopathy driven by AP abnormalities***

C4d staining does not exclude C3G

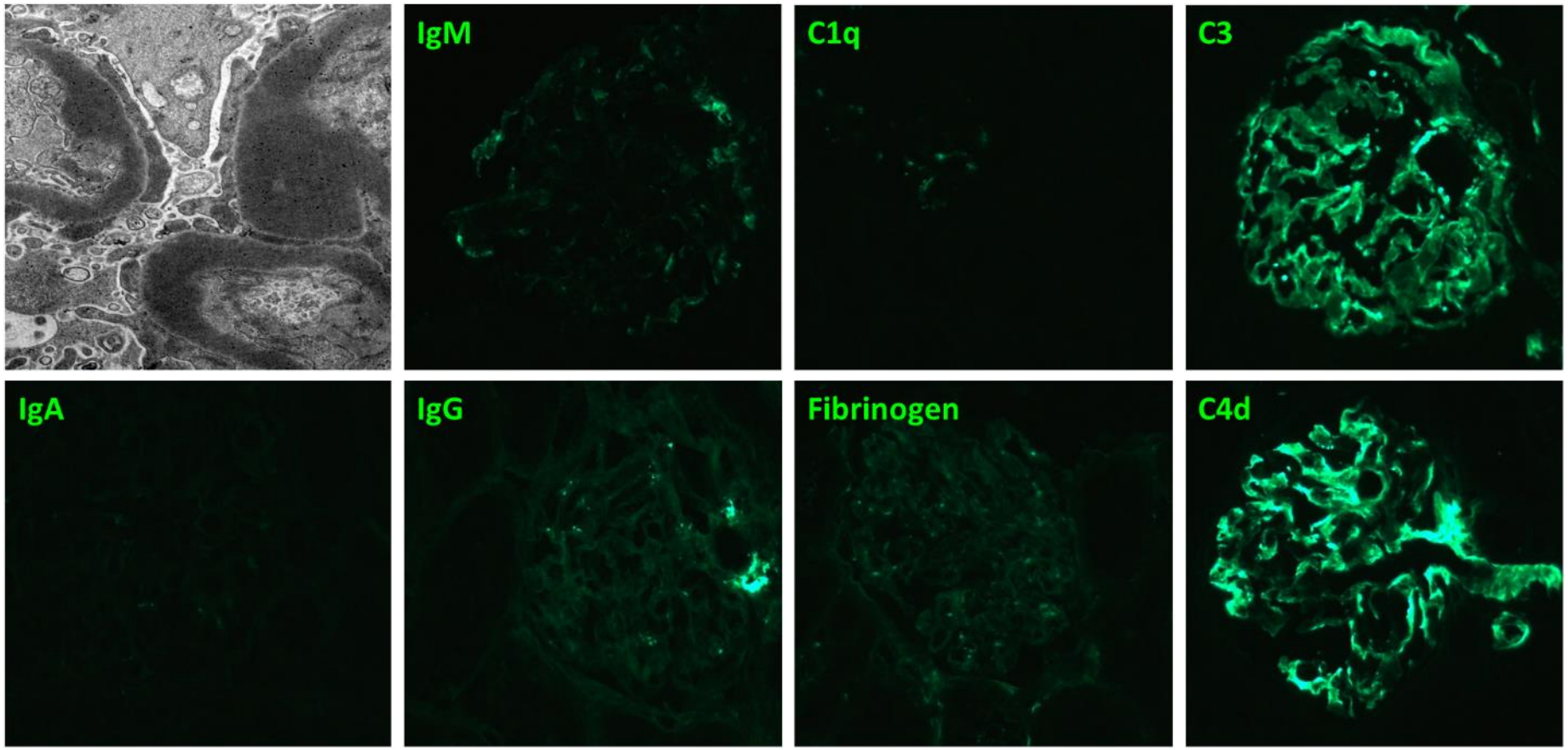

Extrarenal features

Partial lipodystrophy

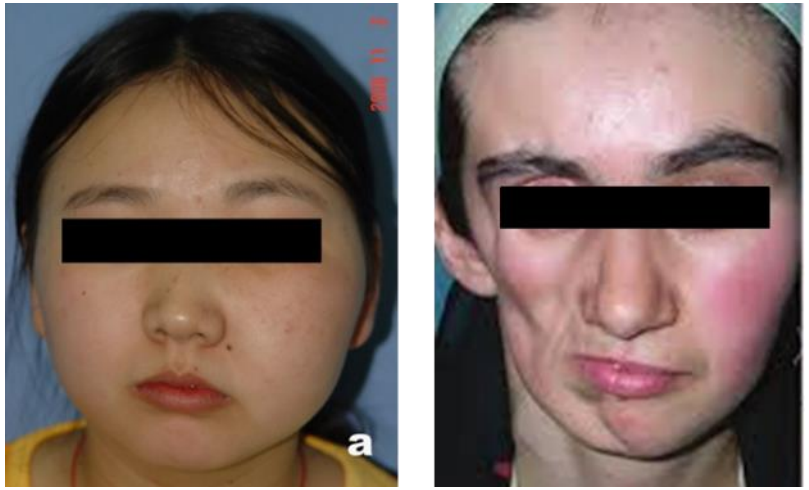

Macula

Drusen

Lipids & proteins

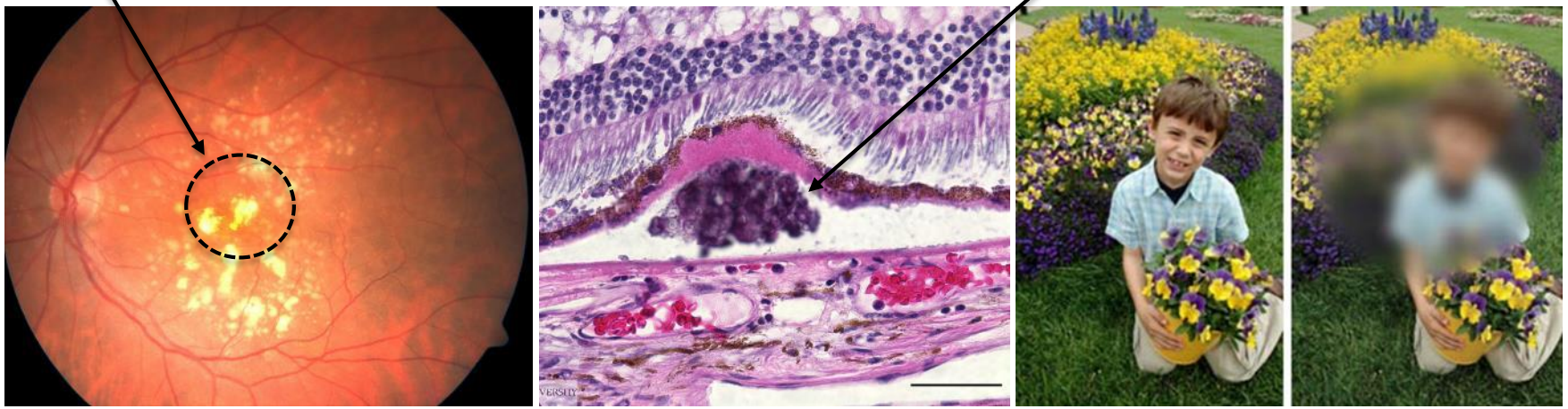

C3G: clinical presentation is heterogenous

- Post-infectious glomerulonephritis with low C3
- Infection triggering macrohematuria, as in IgA nephropathy
- Nephrotic syndrome
- Accidental finding of non-nephrotic proteinuria, microhematuria
- Atypical

C3G presenting as acute PIGN

- **Post-infectious glomerulonephritis with**

1) **low C3 that persists > 12 weeks or with**
2) **recurrent macrohematuria**

Table 3 | Complement abnormalities

Patient	*CFH*	*CFHR5*	FH antibodies[a]	Hemolytic assay[b]	APFA[c]	C3NeF	sMAC[d]
1	c.2171delC, p.Thr724fsX, 725	No mutations	Negative	ND	ND	Negative	0.24 mg/l
2	No mutations	c.646-647, AA>TT, p.Asn216Phe	Negative	0%, Normal	63%, Abnormal	Negative	0.21 mg/l
3	No mutations	No mutations	Negative	1%, Normal	63%, Abnormal	Positive (C3CSAP[e])	ND
4	No mutations	No mutations	Negative	0%, Normal	1% Abnormal	Positive (IFE)	1.23 mg/l
5	No mutations	No mutations	Negative	12% Abnormal	34% Abnormal	Positive (IFE)	0.48 mg/l
6	No mutations	No mutations	Negative	0%, Normal	14% Abnormal	Positive (both assays)	ND
7	c.3350A>G, p.Asn1117Ser	No mutations	Negative	0% Normal	80%	Negative	ND
8	No mutations	No mutations	Negative	0% Normal	123%	Negative	0.13 mg/l
9	No mutations	No mutations	Negative	9% Abnormal	77%	Positive (both assays)	ND
10	c.1699A>G, p.Arg567Gly	No mutations	Negative	0%, Normal	0% Abnormal	Positive (both assays)	2.03 mg/l
11	No mutations	No mutations	Negative	0%, Normal	130%	Positive (C3CSAP)	0.21 mg/l

Sethi, Kidney International 2012

Atypical PIGN is a form of C3G

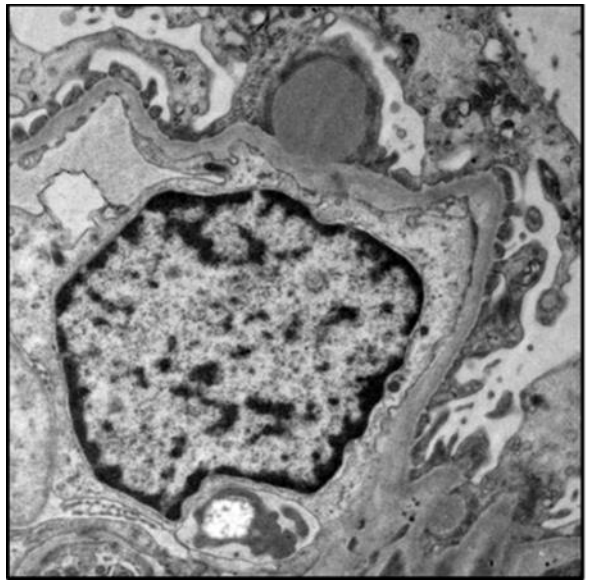

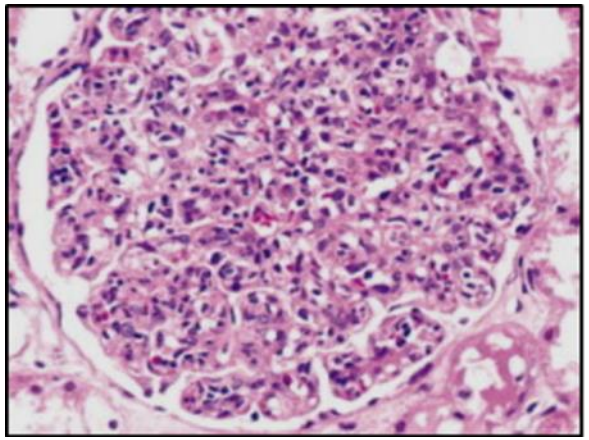

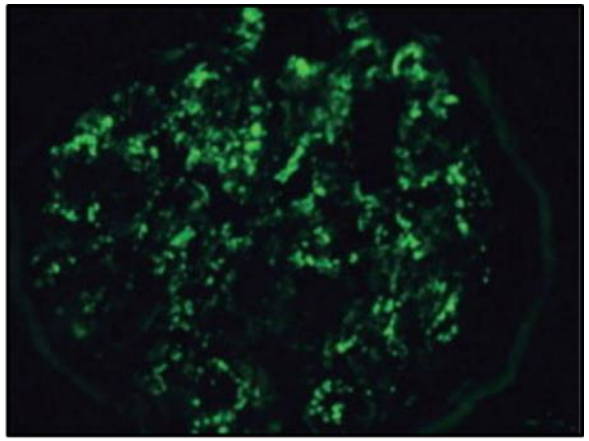

Light microscopy

	PIGN	aPIGN	C3GN
Diff. prol.	+++	+++	-
Mes. prol.	+	+	++
MPGN	-	-	+++
Crescentic	+	+	-

Immunofluorescence

	PIGN	aPIGN	C3GN
C3 capill.	+++	+++	+++
C3 mesang.	+++	+++	+++
IgG	++	+	+/-

Electron microscopy

	PIGN	aPIGN	C3GN
Humps	+++	+++	+
Mesangial	+/-	++	+++
Sub-endoth.	+/-	++	+++

Adapted from Sethi et al, Kidney International 2013

CFHR nephropathy: C3G presenting as “IgA nephropathy”

- **Infection-triggered macrohematuria, proteinuria**

Identification of a mutation in complement factor H-related protein 5 in patients of Cypriot origin with glomerulonephritis

Daniel P Gale*, Elena Goicoechea de Jorge*, H Terence Cook, Rubén Martinez-Barricarte, Andreas Hadjisavvas, Adam G McLean, Charles D Pusey, Alkis Pierides, Kyriacos Kyriacou, Yiannis Athanasiou, Konstantinos Voskarides, Constantinos Deltas, Andrew Palmer, Véronique Frémeaux-Bacchi, Santiago Rodriguez de Cordoba, Patrick H Maxwell†, and Matthew C Pickering†

Lancet 2010

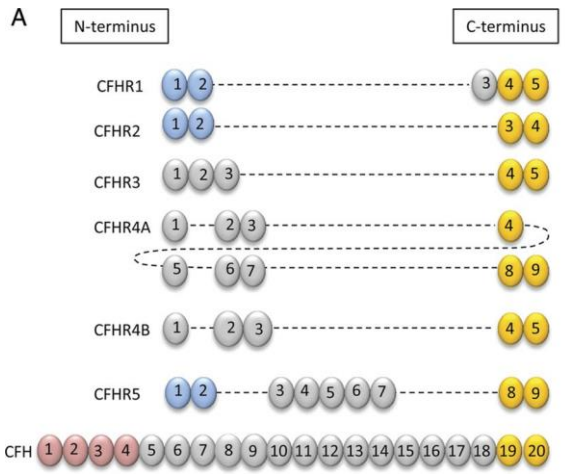

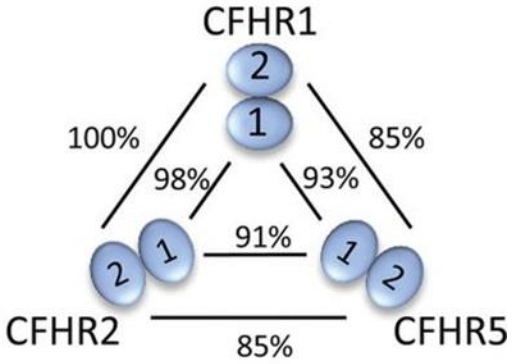

1) CFHR protein mutation

2) Abnormal dimerization

3) FH deregulation

Thomas D. Barbour et al. Nephrol. Dial. Transplant. 2014

C3G can present as nephrotic syndrome

- Post-infectious glomerulonephritis with low C3
- Infection triggering macrohematuria, as in IgA nephropathy
- **Nephrotic syndrome**

A difficult case

- 13-year-old boy
- nephrotic syndrome & hematuria
- markedly low C3 and C4
- initial renal biopsy:
  MPGN with strong C3 deposition
  strong immunoglobulin deposition
- follow-up biopsies (1 and 3 years):
  MPGN with strong C3 deposition
  ± no immunoglobulin deposition
- Elevated sC5b-9
  treated with eculizumab:
  decrease in proteinuria

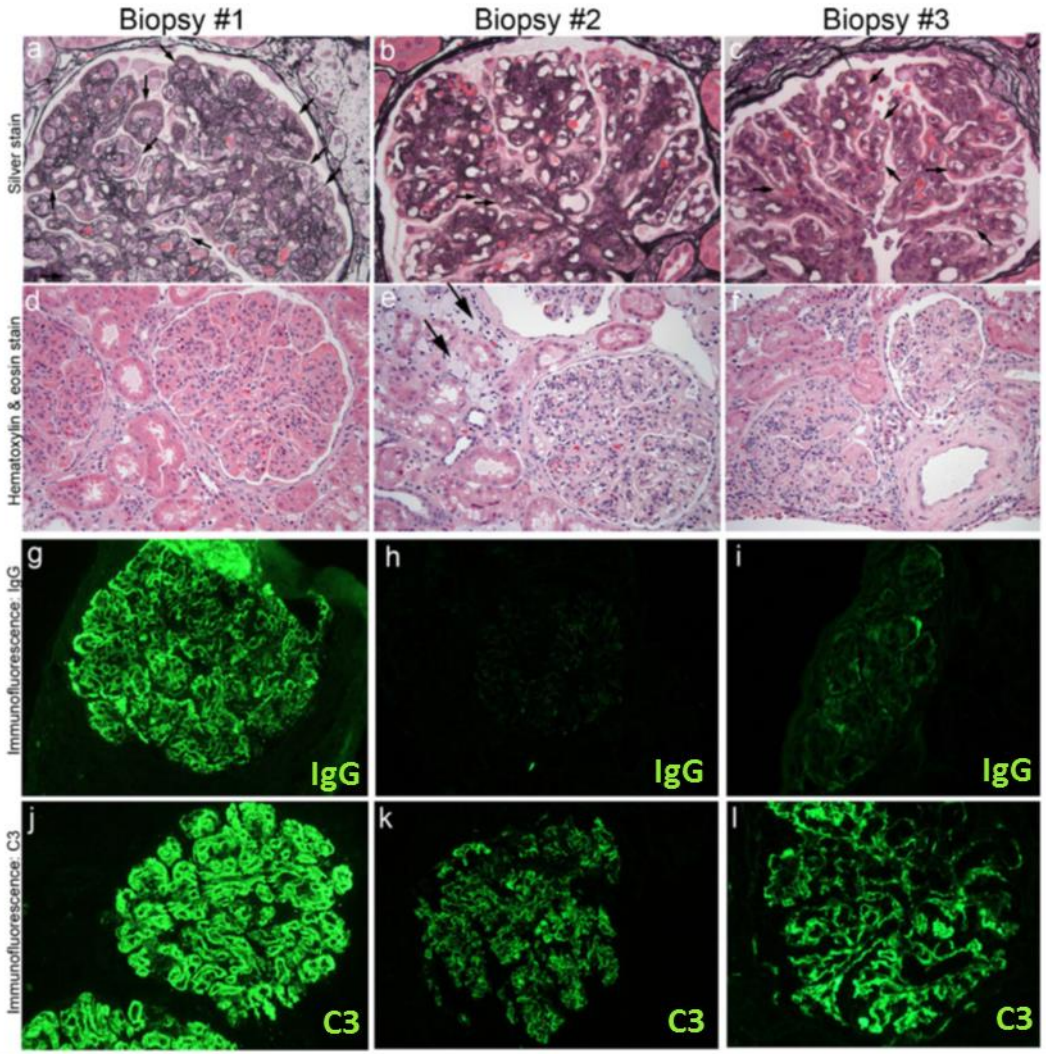

Kerns et al, Ped Nephrol 2013

C3G can be found on routine urinalysis

- Post-infectious glomerulonephritis with low C3
- Infection triggering macrohematuria, as in IgA nephropathy
- Nephrotic syndrome
- **Accidental finding of non-nephrotic proteinuria, microhematuria**

C3G can present as aHUS

- Post-infectious glomerulonephritis with low C3
- Infection triggering macrohematuria, as in IgA nephropathy
- Nephrotic syndrome
- Accidental finding of non-nephrotic proteinuria, microhematuria
- **Atypical**

INITIAL PRESENTATION: aHUS

A 5-year old child was transferred in May 2014 from the Cosenza Pediatric Department with HUS, requiring hemodialysis.

UPON ARRIVAL

He presented with slight confusion, severely hypertensive

- Hb 8.4 g/dl and 66.000 platelets/mmc
- terminal renal failure
- **low C3 (51 mg/dl, normal range 90-180 mg/dl), with normal C4**
- **nephrotic-range proteinuria with red blood cells and casts in the urinary sediment**
- stool culture and serum antibodies were negative for VTEC
- ADAMTS13 levels were slightly reduced (40%)

1) a full workup of complement mutations was performed
2) therapy with **eculizumab** was started

Following start of eculizumab, platelets rapidly increased and after 10 days hemodialysis was discontinued.

However, **renal function remained abnormal with proteinuria in the nephrotic range and persistently low circulating C3**.

Therefore, a renal biopsy was performed, which showed:

Optic Microscopy:

- **No sign of thrombotic microangiopathy, diagnostic of aHUS**
- Mesangial proliferation with increase in matrix
- Endocapillary proliferation and, in 25% of glomeruli, extracapillary proliferation
- Slight tubular atrophy

Immunofluorescence with C3 ++, IgG +/-, fibrinogen +/-, negative IgA, IgM, C1q

Electron Microscopy:
Subendothelial deposits with extensive remodeling of the glomerular capillary walls, signs of chronic damage of arteriolar walls and of chronic TMA

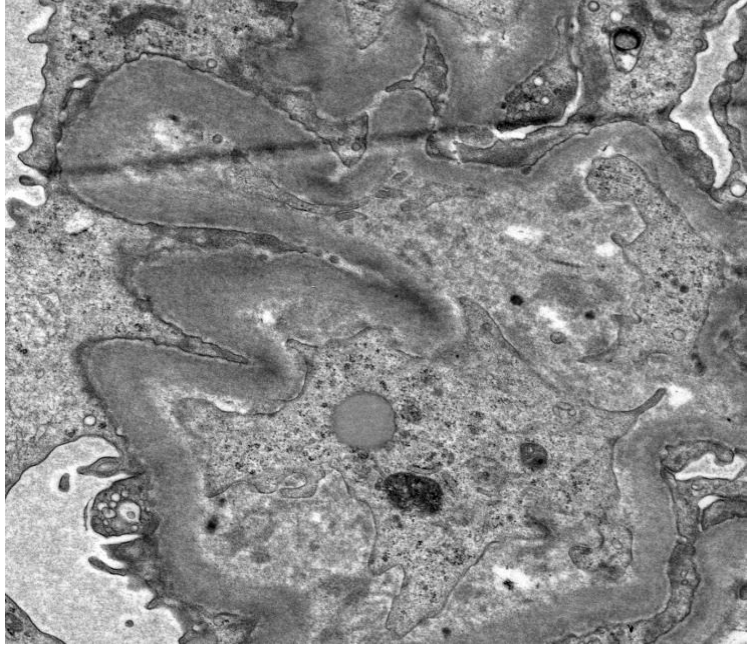

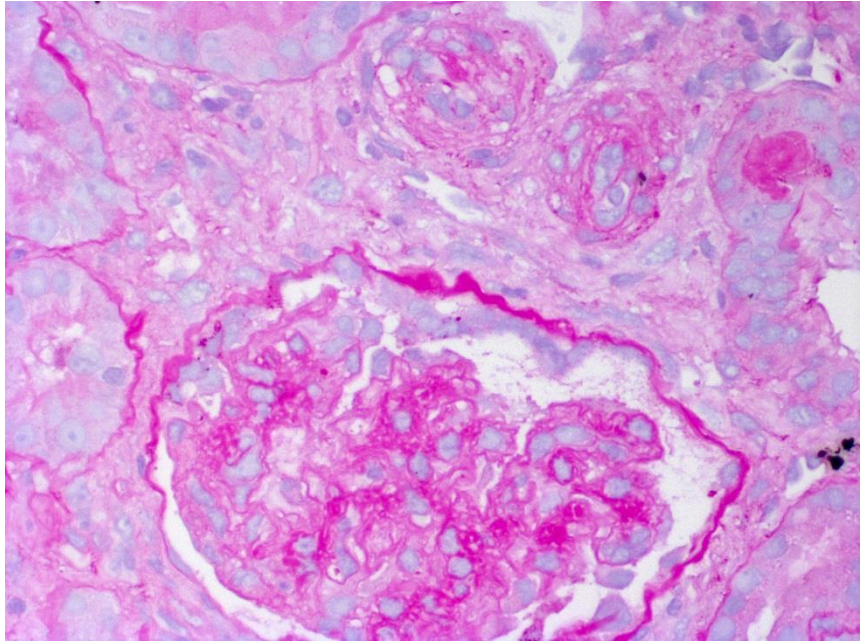

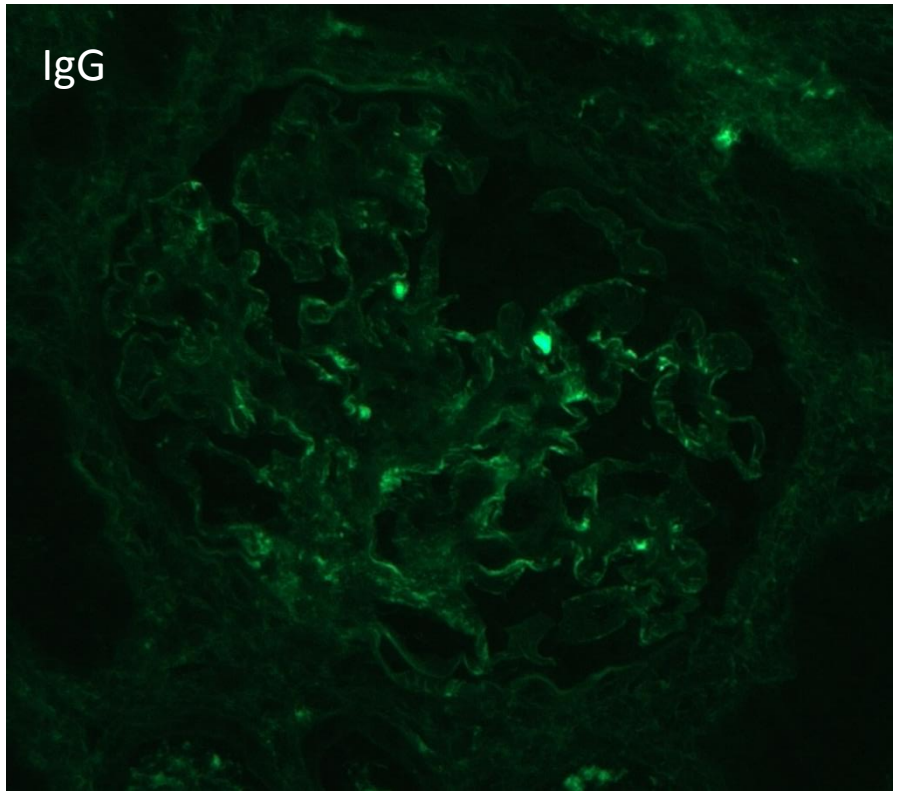
IgG

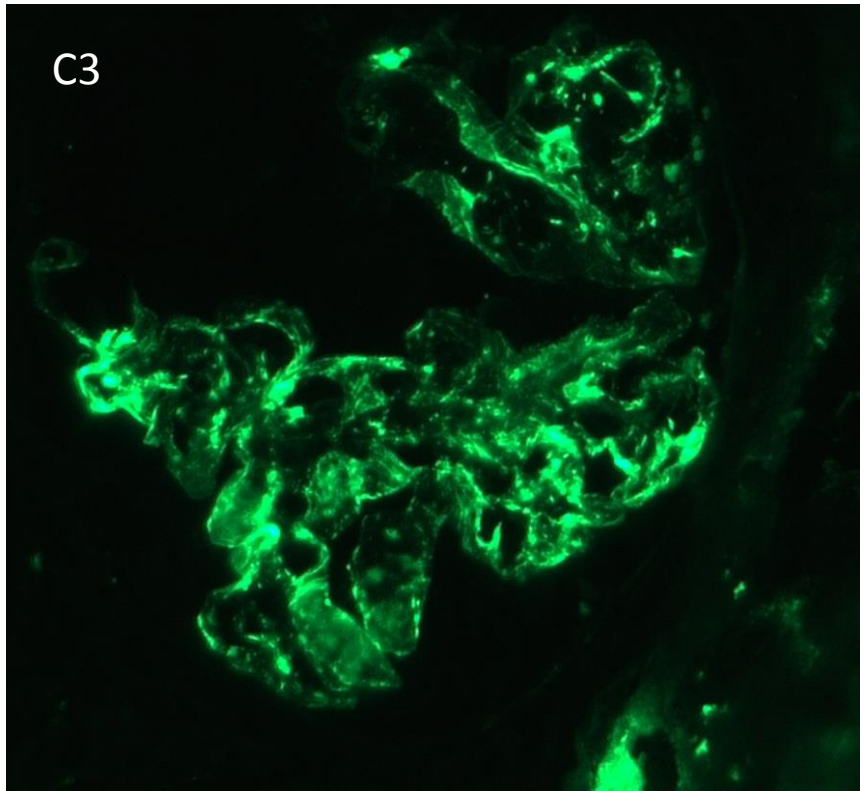
C3

TREATMENT

- 3 i.v. methylprednisolone boluses followed by oral prednisone for 1 month, tapered until discontinuation at 6 months
- continued therapy with eculizumab for 9 months, 3 months after discontinuation of prednisone

This approach led to gradual complete normalization of renal function (in 5 months) and of proteinuria (in 3 months), normal circulating C3, normal complete blood count.

At 6 months a control renal biopsy was performed, showing a marked reduction in mesangial proliferation and in C3 positivity, but a significant sclerosis, global in 10-11/20 glomeruli, focal in 3-4/the remaining glomeruli.

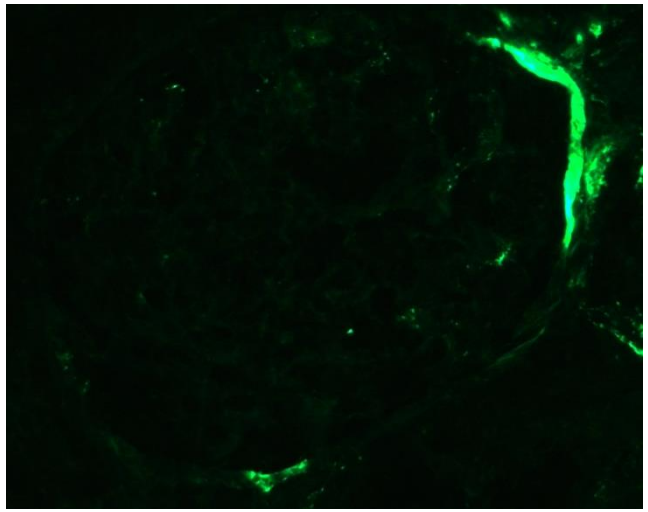

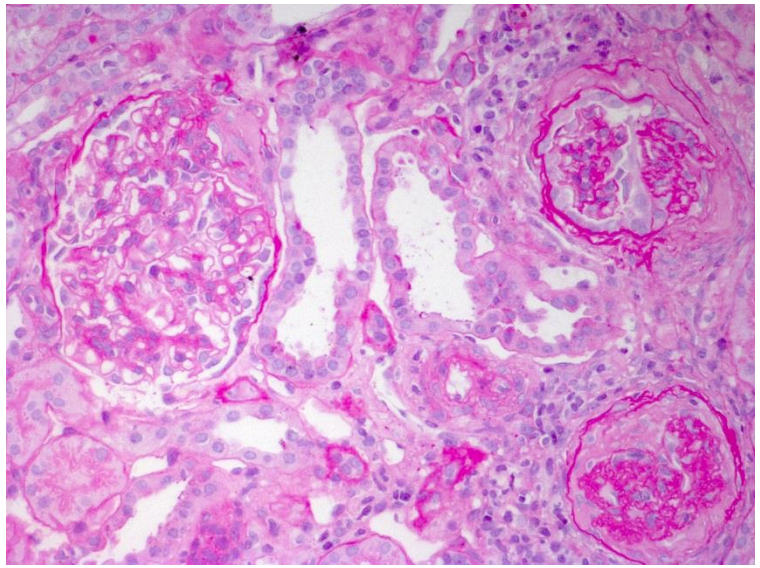

Therapy with eculizumab was discontinued, and until now (30 months later) there is no sign of disease reactivation nor of increase in proteinuria.

Clinical, histological and molecular overlaps

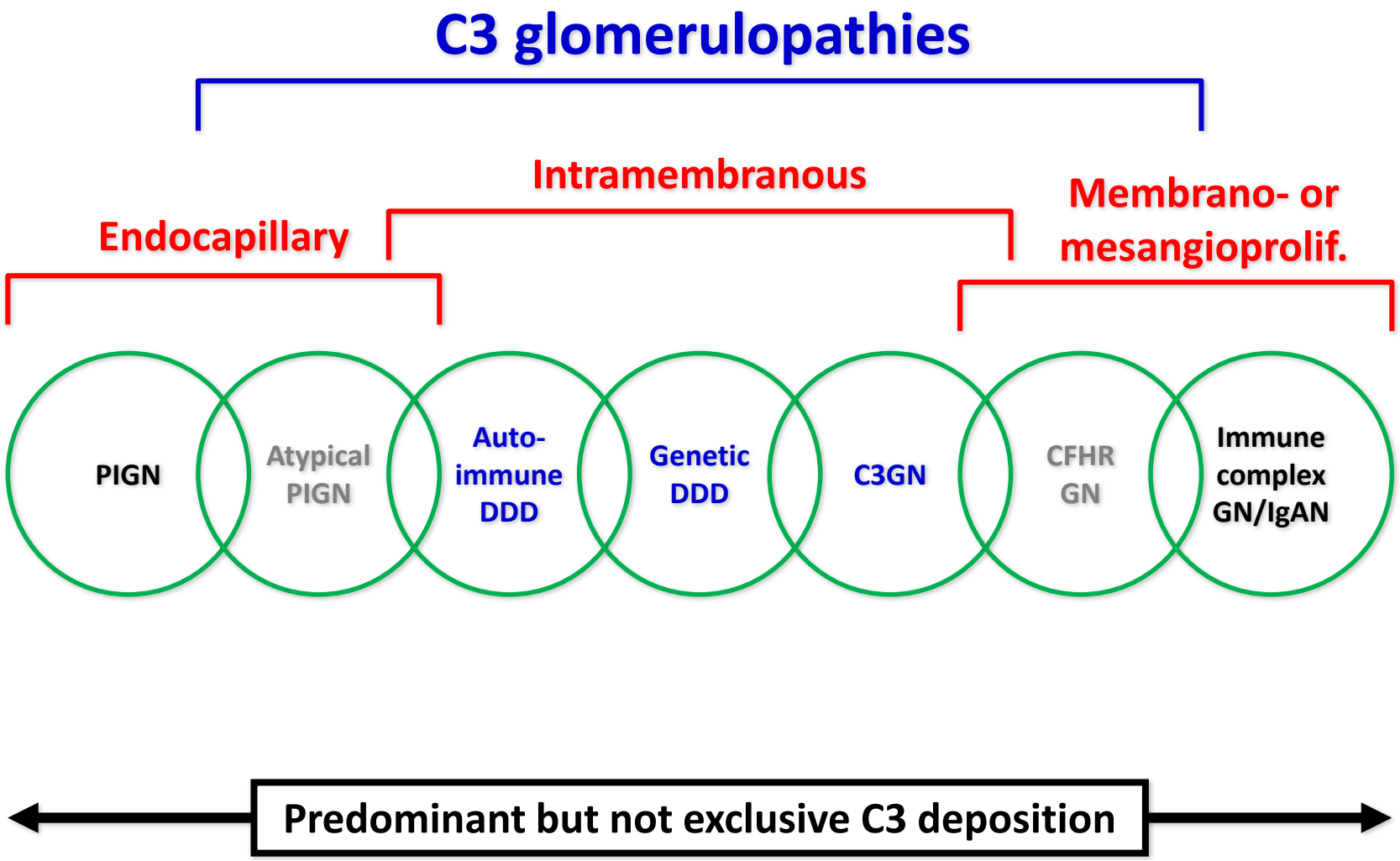

Adapted from Zipfel et al, Molecular Immunology (2015)

C3G: OPBG experience on 32 pediatric patients

Clinical presentation	Urine	Biopsy		Therapy					Outcome	
(number of patients)	M.E.	C3GN	DDD	None	ACEi	PDN	MMF/CsA	ECUL.	PR NoR	CR
Acute PIGN (13)	100%	92%	8%	31%	62%	77%	0%	0%	0%	100%
Nephrotic syndr. (11)	18%	91%	9%	0%	100%	100%	82%	18%	45%	55%
Random urine (8)	0%	50%	50%	13%	88%	50%	13%	0%	13%	88%

C3 glomerulopathy outcome: Servais

Table 1 | Clinical and biological data according to histological type

	All	MPGN 1	DDD	GNC3	*P*-value
N	134	49	29	56	
Sex (M/F)	81/53 (60.4%)	32/17 (65.3%)	17/12 (58.6%)	33/24 (58.9%)	NS
Children[a]/adults	52/82 (38.8%)	21/28 (42.8%)	17/12 (58.6%)	14/42 (25.0%)	NS
Age at diagnosis (years)	24.3 ± 18.6	20.7 ± 16.8	18.9 ± 17.7	30.3 ± 19.3	$<0.05^{c}$ and $<0.01^{d}$
Proteinuria (g/day)	4.9 ± 4.1	6.9 ± 4.4	5.6 ± 4.5	3.6 ± 3.3	$<0.05^{c}$
Nephrotic syndrome	58 (41.1%)	32 (65.3%)	11 (37.9%)	15 (26.8%)	$<0.0001^{c}$ and 0.02^{e}
Microhematuria	83 (58.8%)	25 (51.0%)	22 (75.8%)	36 (64.3%)	NS
HBP	43 (30.5%)	16 (32.6%)	6 (20.7%)	21 (37.5%)	NS
eGFR (ml/min per 1.73 m^2)	69.3 ± 36.6	73.7 ± 33.7	75.5 ± 38.8	65.9 ± 37.4	NS
ACE inhibitor/ARB treatment	64 (45.4%)	27 (55.1%)	10 (34.5%)	27 (48.2%)	NS
Immunosuppressive treatment	61 (43.2%)	28 (57.1%)	14 (48.3%)	19 (33.9%)	0.02^{c}
Follow-up (years)	11.2 ± 11.2	11.7 ± 12.0	12.0 ± 12.1	10.2 ± 10.1	NS
At last follow-up					
eGFR (ml/min per 1.73 m^2)	50.4 ± 39.5	47.7 ± 40.3	53.8 ± 40.3	50.9 ± 37.1	NS
Proteinuria (g/day)	2.2 ± 2.7	2.4 ± 3.5	1.4 ± 1.6	2.1 ± 2.4	NS
Nephrotic syndrome	19 (14.1%)	8 (16.3%)	2 (6.9%)	9 (16.1%)	NS
Duration of evolution until ESRD[b] (years)	10.3 ± 10.2	10.1 ± 9.8	9.8 ± 11.6	10.8 ± 10.0	NS
Dialysis	49 (36.6%)	20 (40.8%)	12 (41.4%)	17 (30.3%)	NS
Age at dialysis (years)	35.6 ± 17.6	30.3 ± 17.2	36.9 ± 18.1	40.8 ± 16.9	NS
Renal transplantation	35 (26.1%)	14 (28.6%)	11 (37.9%)	10 (17.8%)	NS
• Recurrence	18 (51.4%)	6 (42.8%)	6 (54.5%)	6 (60%)	NS
• Thrombotic microangiopathy	6 (17.1%)	2 (14.3%)	3 (27.3%)	1 (10.0%)	NS
• Vascular rejection	2 (5.8%)	1 (7.1%)	0 (0%)	1 (10.0%)	NS

Servais A, KI 2012

Risk factors of poor long-term outcome in C3G

Multivariate analysis of the association of long-term renal outcome with clinical, laboratory and genetic features.

	All patients		
	HR	HR 95%CI	*p*
Absence of mutations or C3NeFs	7.1	1.9–26.3	0.004
Sclerotic glomeruli (% of glomeruli)	69.3	3.1–1553	0.008
Crescents (% of glomeruli)	39.7	3.3–481	0.004
Nephrotic syndrome at onset	10.9	2.5–47	0.002

HR: hazard ratio calculated by Multivariate Cox proportional-Hazards analysis. CI: confidence Interval.nc: not calculable. Nephrotic syndrome was defined as: 24-h proteinuria exceeding 3.5 g in adults or 40 mg/h/m2 in children together with albuminemia ≤3 g/dL. Intensified immunosuppression was also included in multivariate Cox Regression analysis but was not significantly associated with progress to ESRD (HR = 3.9, 95%CI 0.65–23.9, $p = 0.138$).

Iatropoulos et al, Mol Immunol 2016

How to treat C3G?

Inflammation !

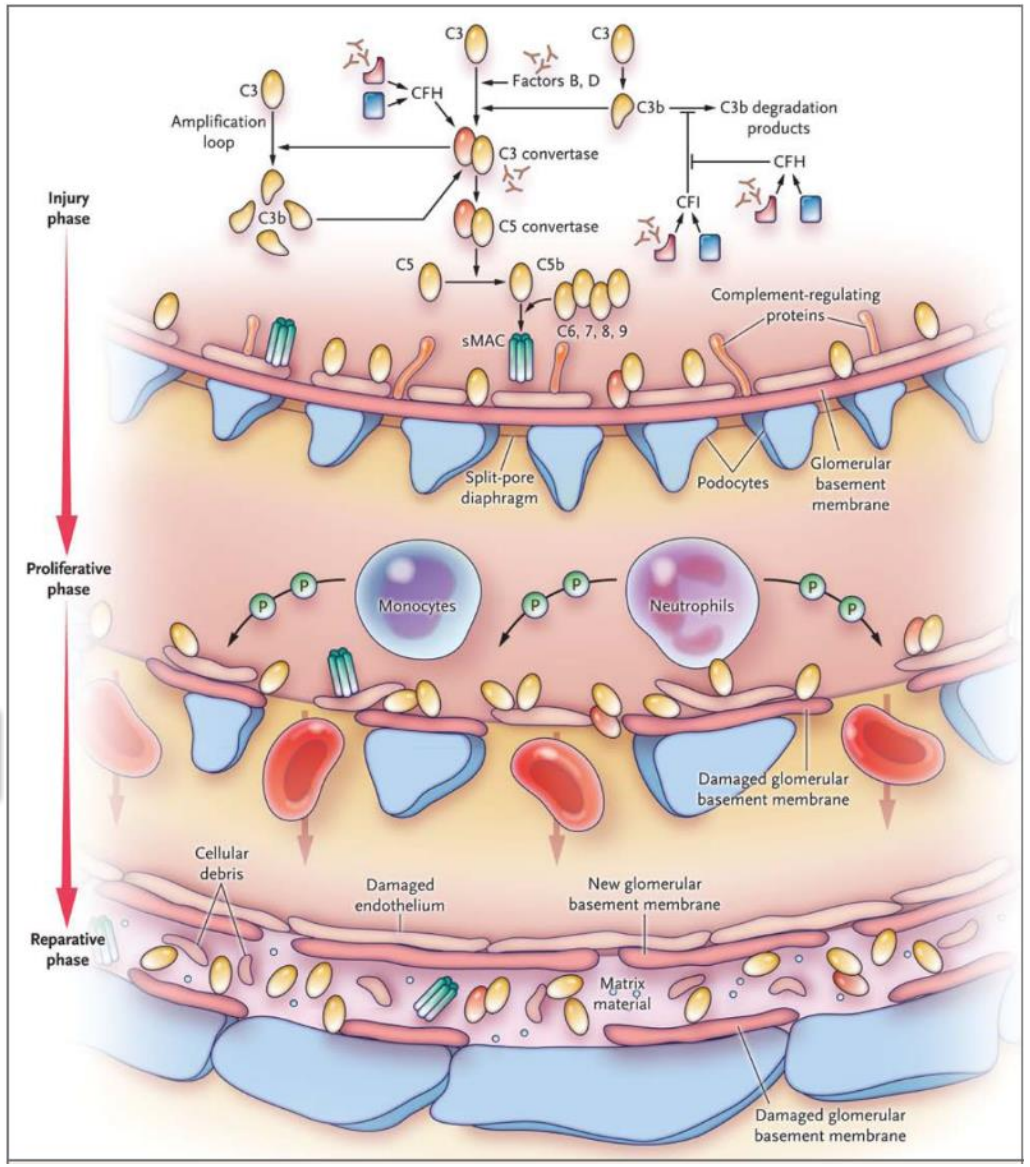

Sethi S, Fervenza FC NEJM 2012

Treatment of C3G: mycophenolate

Effectiveness of mycophenolate mofetil in C3 glomerulonephritis

Cristina Rabasco[1], Teresa Cavero[1], Elena Román[2], Jorge Rojas-Rivera[3], Teresa Olea[4], Mario Espinosa[5], Virginia Cabello[6], Gema Fernández-Juarez[7], Fayna González[8], Ana Ávila[9], José María Baltar[10], Montserrat Díaz[11], Raquel Alegre[3], Sandra Elías[12], Monserrat Antón[13], Miguel Angel Frutos[14], Alfonso Pobes[15], Miguel Blasco[16], Francisco Martín[17], Carmen Bernis[18], Manuel Macías[19], Sergio Barroso[20], Alberto de Lorenzo[21], Gema Ariceta[22], Manuel López-Mendoza[6], Begoña Rivas[4], Katia López-Revuelta[7], José María Campistol[16], Santiago Mendizábal[2], Santiago Rodríguez de Córdoba[23] and Manuel Praga[1,24] for the Spanish Group for the Study of Glomerular Diseases (GLOSEN)

KI 2015; 88(5):1153-60

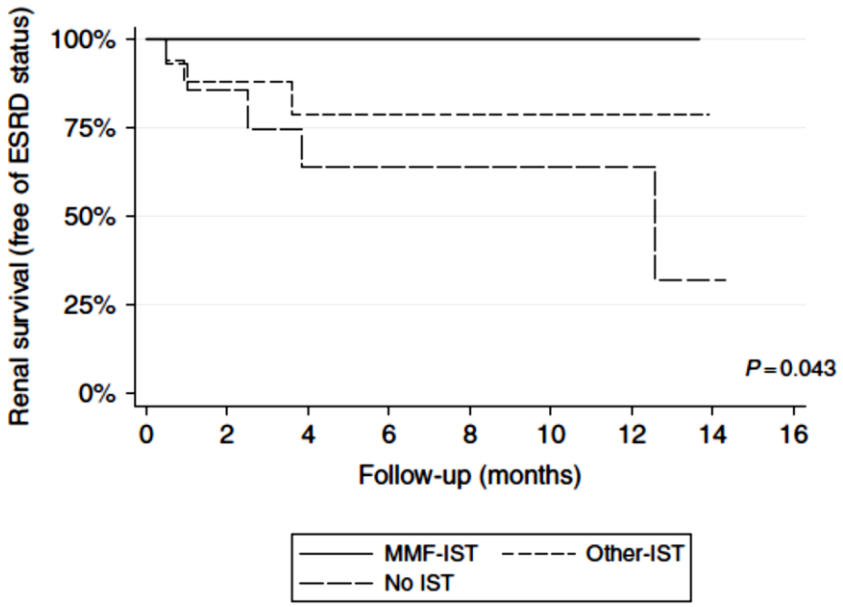

	Patients at risk according to months of follow-up								
Group of treatment	0	2	4	6	8	10	12	14	16
MMF-IST	22	15	10	5	4	4	2	1	1
Other-IST	18	13	10	6	4	2	2	1	1
No IST	20	14	11	7	6	6	5	4	3

Figure 1 | Renal survival (defined by a status free of end-stage renal disease) in patients treated with MMF (MMF-IST), other IST (other-IST), and no IST (non-IST). ESRD, end-stage renal disease; IST, immunosuppressive treatments; MMF, mycophenolate mofetil.

Treatment of C3G: KDIGO guidelines

www.kidney-international.org meeting report

Atypical hemolytic uremic syndrome and C3 glomerulopathy: conclusions from a "Kidney Disease: Improving Global Outcomes" (KDIGO) Controversies Conference

OPEN

Timothy H.J. Goodship[1], H. Terence Cook[2], Fadi Fakhouri[3], Fernando C. Fervenza[4], Véronique Frémeaux-Bacchi[5], David Kavanagh[1], Carla M. Nester[6,7], Marina Noris[8], Matthew C. Pickering[2], Santiago Rodríguez de Córdoba[9], Lubka T. Roumenina[10,11,12], Sanjeev Sethi[13] and Richard J.H. Smith[6,7]; for Conference Participants[14]

Table 5 | Recommended treatment approach for C3G[a]

All patients	• Optimal blood pressure control (suggested blood pressure below the 90% in children and ≤120/80 mm Hg in adults) ○ Priority agents include angiotensin converting enzyme inhibitors and angiotensin receptor blockers • Optimal nutrition for both normal growth in children and healthy weight in adults • Lipid control
Moderate disease	**Description** • Urine protein over 500 mg/24 h despite supportive therapy *or* • Moderate inflammation on renal biopsy *or* • Recent increase in serum creatinine suggesting risk for progressive disease **Recommendation** • Prednisone • Mycophenolate mofetil
Severe disease	**Description** • Urine protein over 2000 mg/24 h despite immunosuppression and supportive therapy *or* • Severe inflammation represented by marked endo- or extracapillary proliferation with or without crescent formation despite immunosuppression and supportive therapy *or* • Increased serum creatinine suggesting risk for progressive disease at onset despite immunosuppression and supportive therapy **Recommendation** • Methylprednisolone pulse dosing as well as other anti-cellular immune suppressants have had limited success in rapidly progressive disease • Data are insufficient to recommend eculizumab as a first-line agent for the treatment of rapidly progressive disease

C3G, C3 glomerulopathy.
[a]Based on a single, small prospective trial, case reports, and expert opinion.

Goodship KI 2017

Complement-targeting therapies: anti-C5 blocks the terminal complement pathway

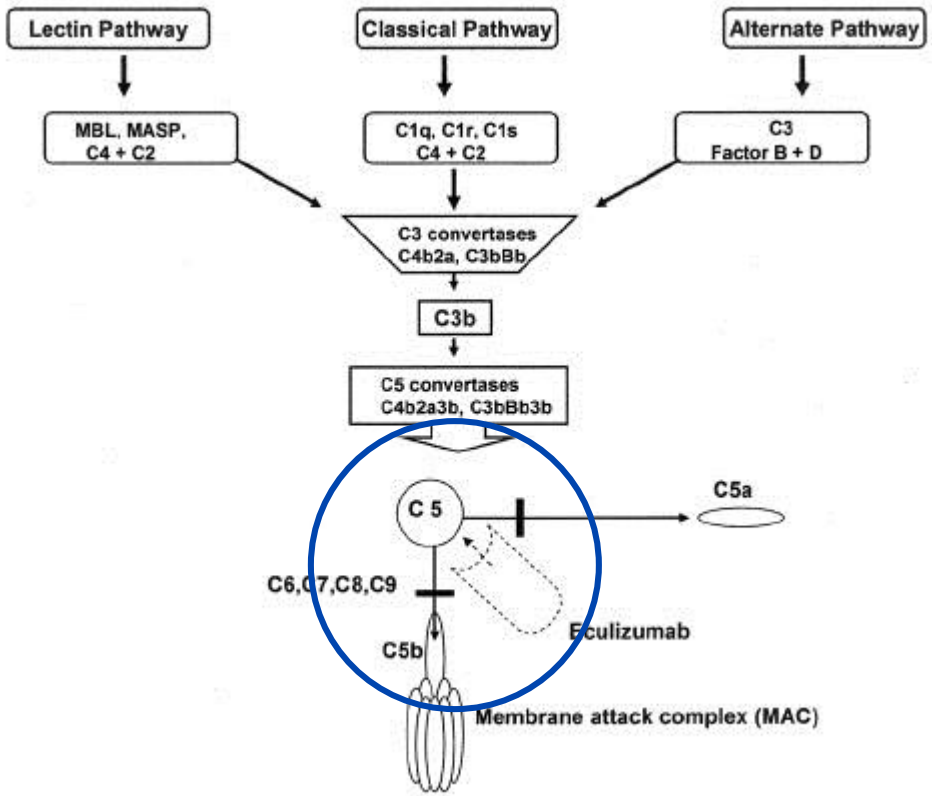

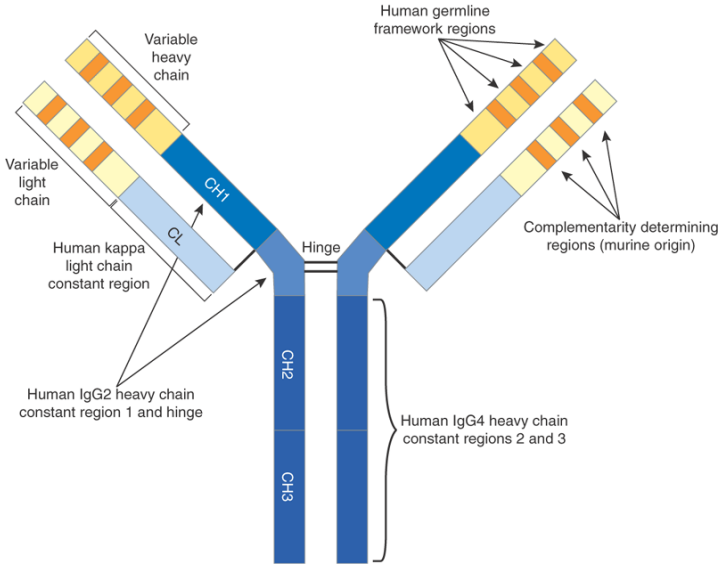

Rother et al. Nature Biotechnology 2007

Treatment of DDD with anti-C5 (eculizumab)

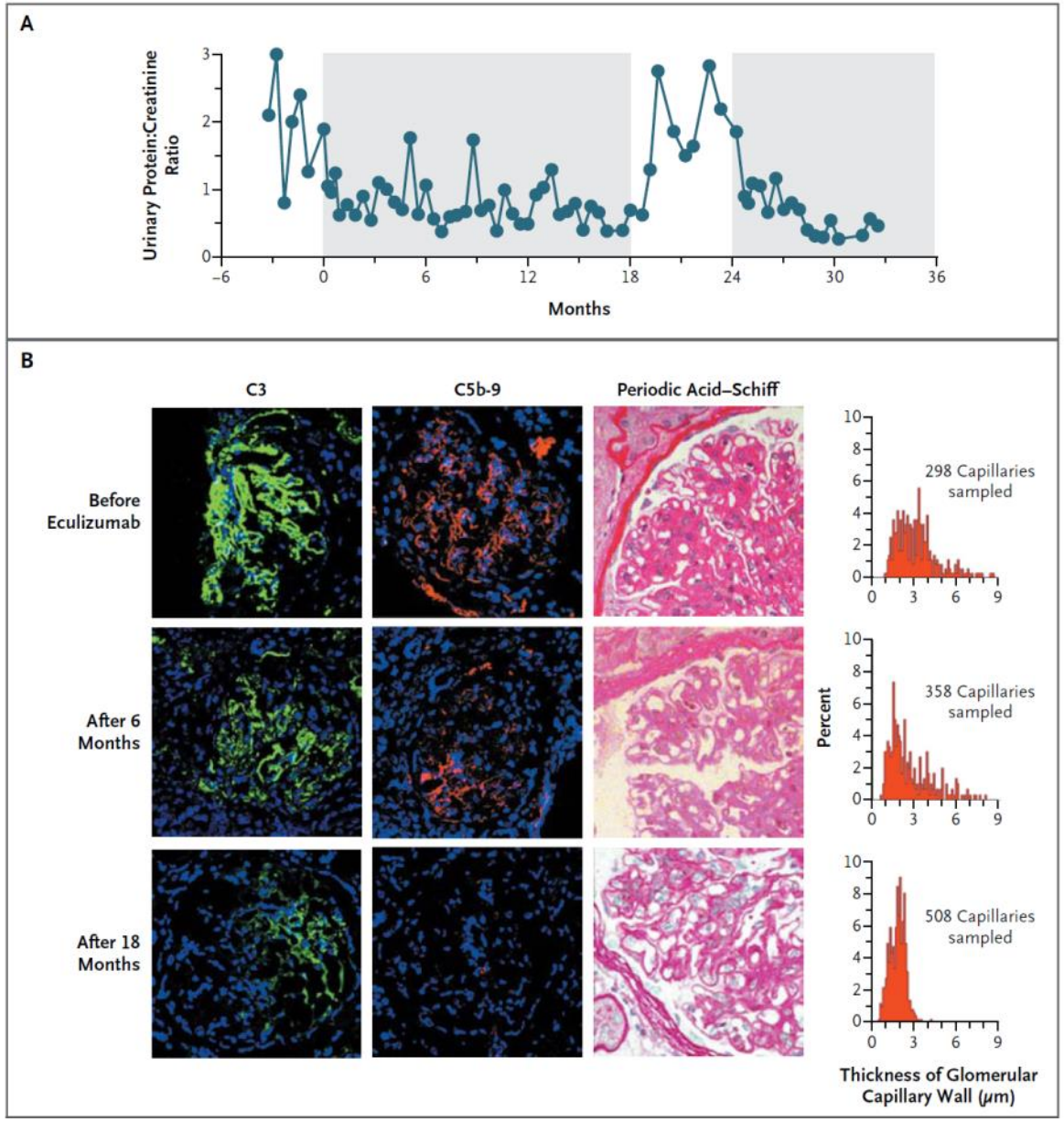

ATTENTION:

- **not all patients respond so well**
- **it may work better in those with elevated sC5b9**
- **expensive and there is a risk of meningococcal infection**

Figure 1. Change in the Patient's Urinary Protein:Creatinine Ratio, the Glomerular Deposition of C3 and C5b-9, and the Thickness of Glomerular Capillary Walls before Treatment and after 6 and 18 Months of Treatment.

Panel A shows the changes in the patient's urinary protein:creatinine ratio (mg/mg), starting 6 weeks before the first eculizumab infusion. The shaded areas represent the time during which the patient was undergoing treatment with eculizumab and the white areas the time before therapy began and the period during which therapy was discontinued. Panel B shows stained specimens from renal biopsies performed before treatment with eculizumab and at 6 and 18 months during the first treatment period. During this period, the clearance of C3 and C5b-9 deposition is nearly complete (C3 is shown in green fluorescence and C5b-9 in red fluorescence; nuclei are stained in blue); histologic improvement is revealed with periodic acid–Schiff staining. The far right column shows the progressive reduction in the thickness of the glomerular capillary walls in response to treatment. Capillary thickness was estimated by observing the width of positive periodic acid–Schiff staining in all peripheral capillary loops of analyzed glomeruli; the number of capillaries sampled at the time of each biopsy is provided.

Vivarelli et al, New England J Med 2012

Circulating C3 and C5b-9 according to renal histology

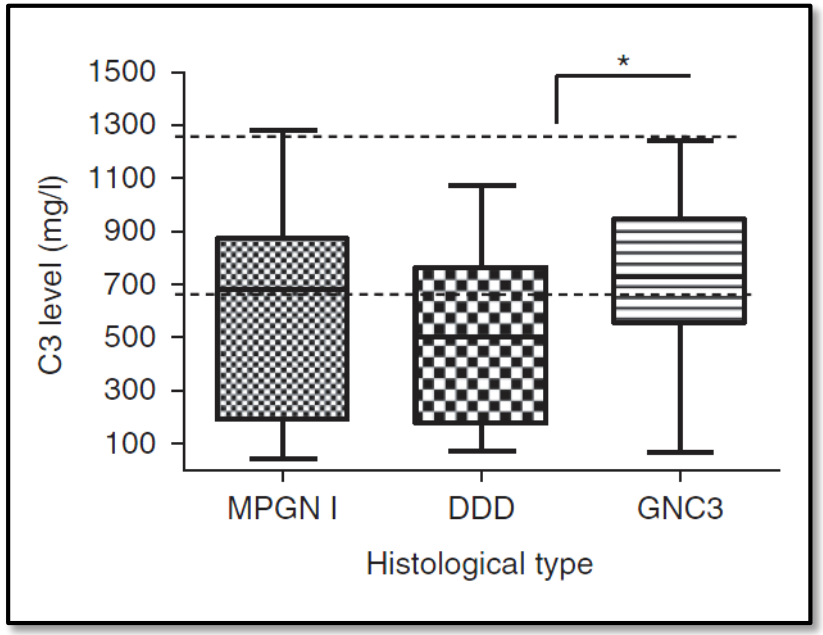

Servais et al, Kidney Int 2012

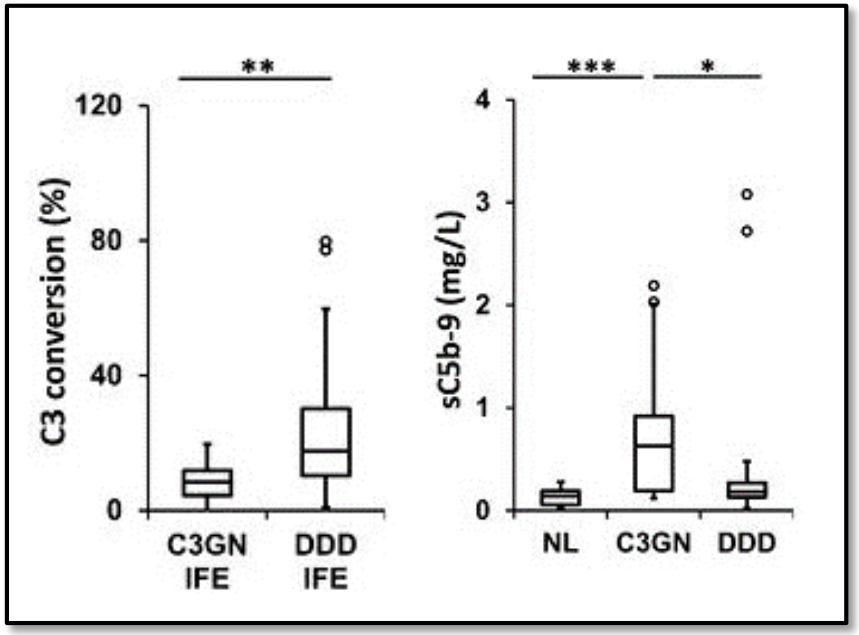

Yuzhou Zhang et al. CJASN 2014

C3 convertase dysregulation:
DDD>C3GN

C5 convertase dysregulation:
C3GN>DDD

Complement-targeting therapies on the horizon

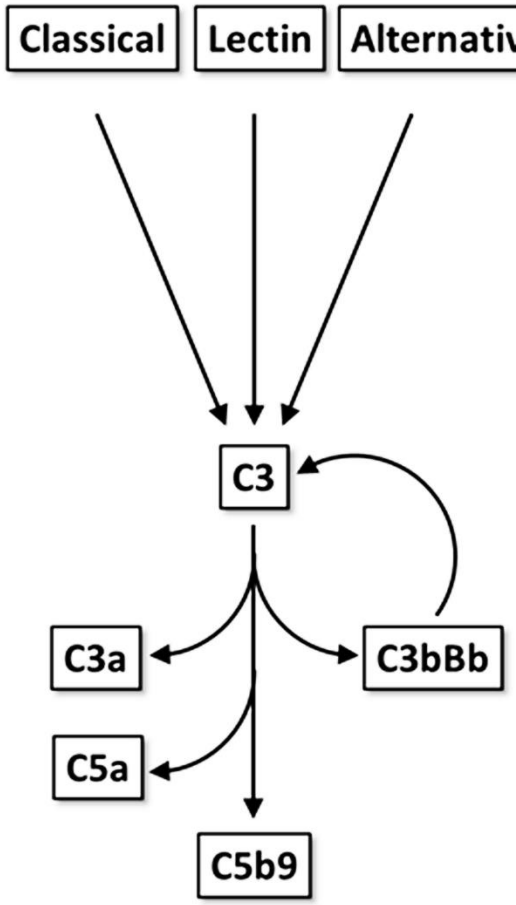

DISEASE	COMPLEMENT-TARGETING THERAPIES
IC-MPGN C3G IgAN IMN	Soluble CR1 Anti-Factor B Anti-Factor D Anti-Properdin Anti-C3 (Compstatin) Aurin tricarboxylic acid
AAV GPA	Anti-C5 C5 siRNA C5aR antagonist (CCX168)
aHUS	Anti-C5a Anti-C5 Aurin tricarboxylic acid

Courtesy Christoph Licht

Take-home messages

1) Complement involvement is being found in a growing number of kidney diseases

- Permanent (genetic) as in aHUS, genetic forms of C3G
- Transitory (infectious trigger) as in PIGN
- Concomitant to an immune-mediated mechanism such as in antibody-mediated C3G, IC – MPGN, lupus nephritis, AAV / GPA, IgAN, MN, APL, humoral rejection

2) C3G is extremely heterogenous and less rare than we thought. Some cases may spontaneously improve. Some patients have a relapsing course.

3) Treatment of C3G should be tailored on a pathogenetic basis to target the involved mediator. Immunosuppressive drugs (PDN, MMF) may be beneficial both to treat the immune-mediated mechanism, if present, and if there is evidence of renal inflammation

4) Anti-C5 therapy may be beneficial in some, but not in all patients

THANK YOU

- Prof Joshua Thurman
- Prof Carla Nester
- Prof Christoph Licht

- Dr Marina Noris
- Dr Elena Bresin
- Dr Veronique Fremeaux-Bacchi

- Prof Francesco Emma

The patients and their families

Bambino Gesù
OSPEDALE PEDIATRICO