Renal manifestations related to *COL4A1* mutations

ERKNet
The European
Rare Kidney Disease
Reference Network

Webinar March 7, 2019

Pr Emmanuelle PLAISIER

Department of Adult Nephrology
Tenon's Hospital – Sorbonne Université- INSERM
Paris – France

Collagen IV

- Network-forming collagen
- Main basement membrane (BM) component
- Six isoforms : $\alpha 1$ to $\alpha 6$ (IV) chains,

  3 heterotrimers : $\alpha 1 \alpha 1 \alpha 2$, $\alpha 3 \alpha 4 \alpha 5$, $\alpha 5 \alpha 5 \alpha 6$

Collagen IV

- Network-forming collagen
- Main basement membrane (BM) component
- Six isoforms : α1 to α6 (IV) chains,

  3 heterotrimers : α1α1α2, α3α4α5, α5α5α6

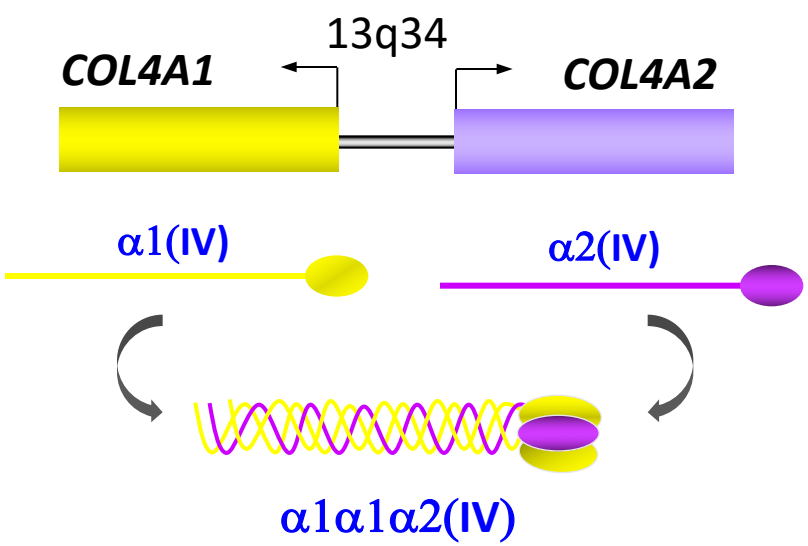

Ubiquitous BM expression

Muscle	Adipose tissue
Vessels	Nervous system
Eye	Kidney…..

Collagen IV *in the kidney*

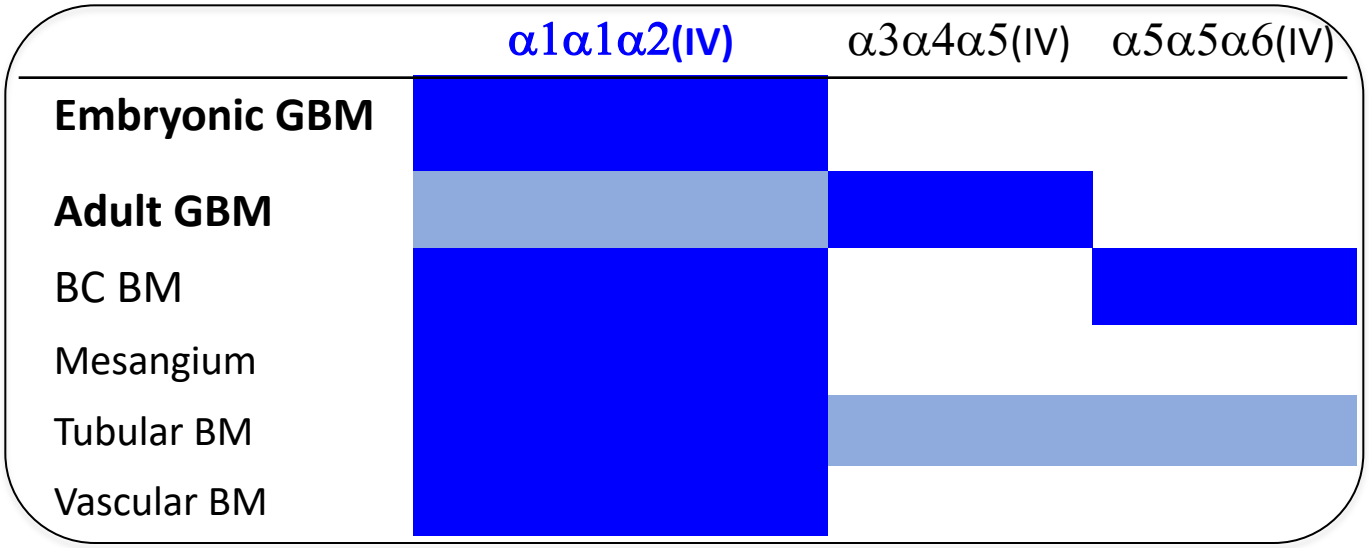

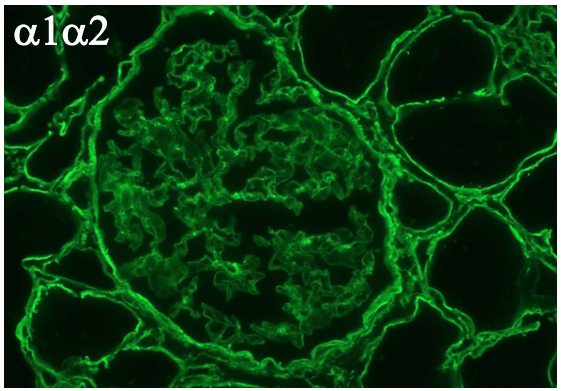

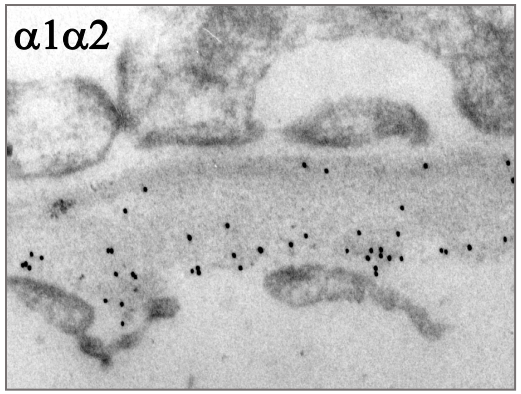

Podocytes

Glomerular BM

Capillary lumen

Human adult kidney

Inherited collagen IV diseases

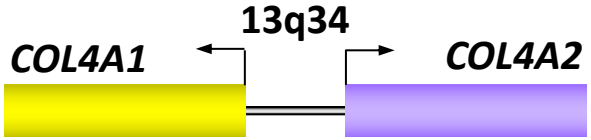

AD/AR Alport Syndrome
Progressive Familial Hematuria
AD FSGS
Benign Familial Hematuria

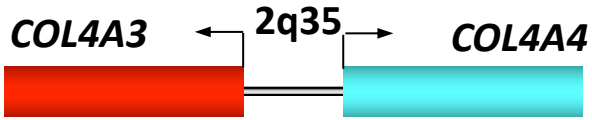

X -linked Alport Syndrome

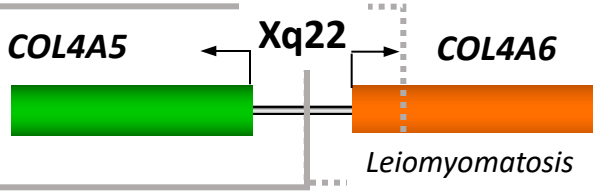

Inherited *COL4A1/COL4A2* diseases

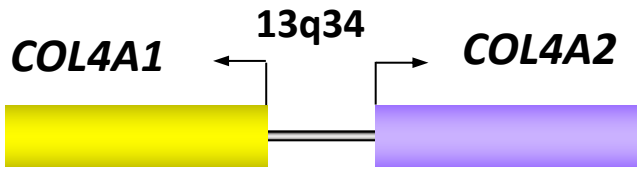

Cerebral small vessel disease with eye defects

Gould DB, Science 2005
Gould DB, NEJM 2006

Cerebral small vessel disease with eye defects

Yoneda Y, Am J Hum Genet, 2013
Jeanne M, Am J Hum Genet, 2013

Microphtalmia and/or Eye anterior segment dysgenesis

Deml B, Clin Genet, 2014

HANAC syndrome

Plaisier E, NEJM, 2007

Inherited *COL4A1* diseases

- **Autosomal dominant transmission**
- **Unknown frequency**
- **Underdiagnosed in pauci-symptomatic forms**
- **Huge phenotypic variability**
  - Within/between families
  - Single organ or multisystemic involvement
  - Age at the first manifestations
  - Severity

  from antenatal intracerebral bleeding to clinically silent throughout life

- **Mostly a multisystemic disease** ⟹ *Systematic evaluation at diagnosis during follow-up*
  - Cerebral and retinal vasculopathy
  - Eye defects
  - ***Kidney disease***
  - Muscle symptoms…

Cerebral manifestations (1)

Cerebral small vessel disease

Clinical symptoms

Neonatal to adult onset

- Silent
- Migraine
- Epilepsy
- Stroke (haemorrhagic> ischemic)
- Congenital hemiplegia
- Intellectual disability

Brain lesions (MRI)

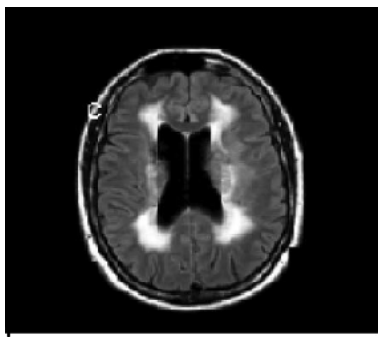

Leukoencephalopathy

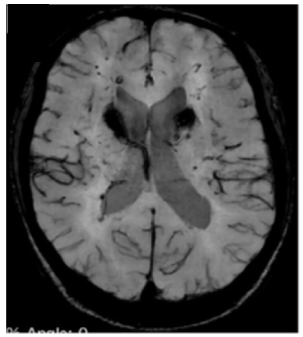

Microbleeds

Lacunar infarct – Brain calcifications

Intracerebral haemorraghes

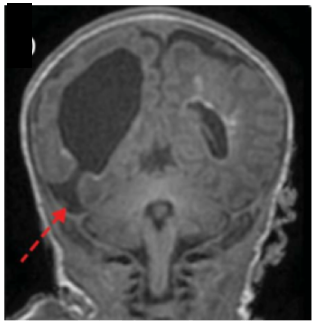

Porencephaly
Schizencephaly

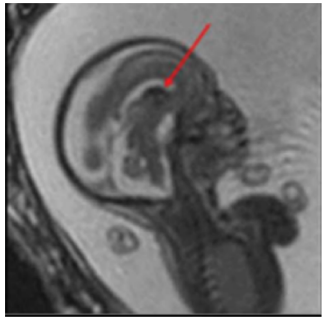

Fetal brain haemorrhage

Gould DB, Nature 2005
Gould DB, NEJM, 2006
Sondergard CB, Cli Neurol Neurosur, 2017
Cavillon M, Eur J Med Genet, 2018
Zagaglia S, Neurology, 2018

Cerebral manifestations (2)

Intracranial aneurysms

- < 10 % of patients
- Unique or multiple
- Mostly in the intracranial portion of the internal carotid artery
- No episode of rupture

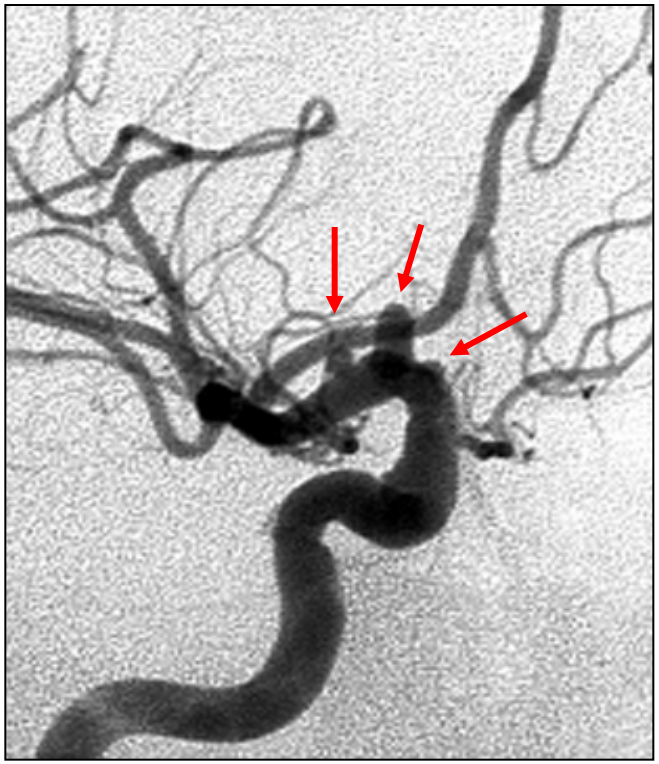

Plaisier E, NEJM, 2007
Plaisier E, Am J Med Genet, 2010
Giorgo E, J Neurol Sci, 2015
Meuwissen ME, Genet Med, 2015

Eye defects

- **Congenital cataracts**

- **Anterior eye dysgenesis –** Axenfeld-Rigger type

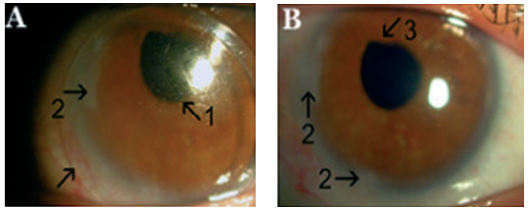

  - Iris abnormalities
  - Microcornea
  - Microphtalmia
  - Glaucoma

- **Retinal arteriolar tortuosity**

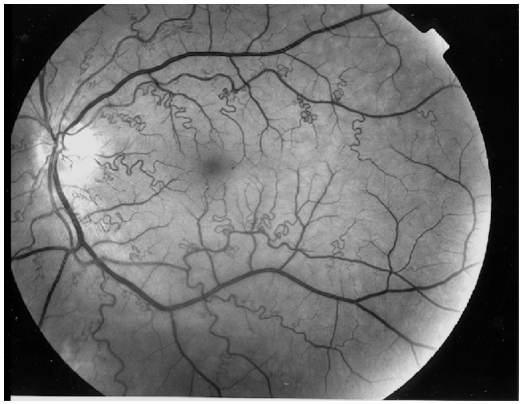

  - Bilateral
  - Episodes of retinal haemorrhages
  - No visual impact

Matias-Perez D, J Hum Genet, 2018
Khan MA, JAMA Ophtalmol, 2016
Slavotinek AM, Clin Genet 2015
Deml B, Clin Genet 2014
Sibon I, Ann Neurol, 2007

Other extra-renal manifestations

- **Muscle cramps**
  - Onset in early childhood
  - Diffuse
  - +/- increased by cold temperature
  - No muscle weakness
  - No specific histological changes of skeletal muscle
- Elevated serum creatine kinase (even in the absence of cramps)
- Raynaud phenomena
- Supraventricular arrythmia

Plaisier E, NEJM, 2007
Plaisier E, Am J Med Genet, 2010
Meuwissen ME, Genet Med, 2015
Zagaglia D, Neurology, 2018

Renal manifestations

(1) Multicystic kidney disease

- Bilateral cysts
- Variable in number and size
- Growing in size with age
- Normal kidney size
- No complication
- Normal eGFR to ESRD…
- ***Not usually associated with hematuria***
- (No liver cyst)

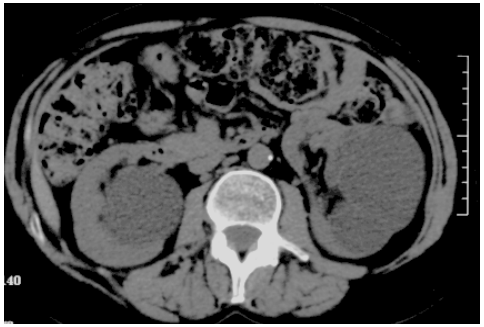

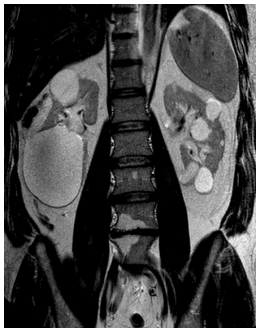

57 years - eGFR = 72 ml/min/1,73m^2

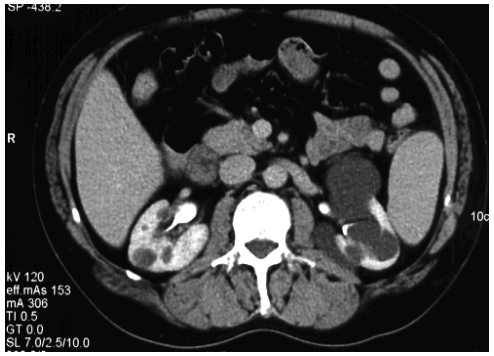

51 years - eGFR = 48 ml/min/1,73m^2

….. 61 ans - ESRD

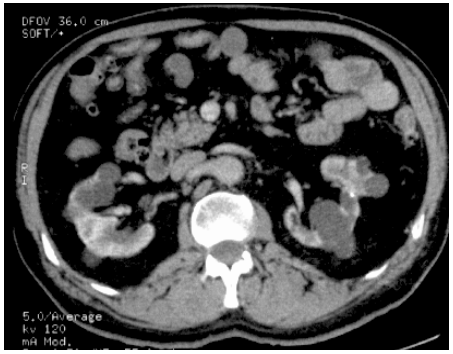

62 years - eGFR = 32 ml/min/1,73m^2

Plaisier E, NEJM, 2007
Plaisier E, Am J Med Genet, 2010
Gale DP, NDT, 2015

Renal manifestations

(1) Multicystic kidney disease

(2) Hematuria

Plaisier E, Kidney Int, 2005
Plaisier E, NEJM, 2007
Gale DP, NDT, 2015

- Intermittent or permanent
- Rarely gross episodes
- May be first detected in early childhood
- No proteinuria/albuminuria
- Normal blood pressure
- ***Inconstantly associated with cysts***

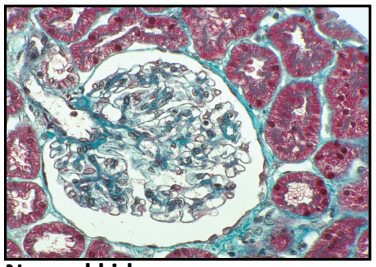

Normal kidney

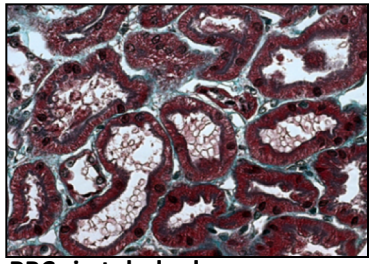

RBCs in tubular lumen

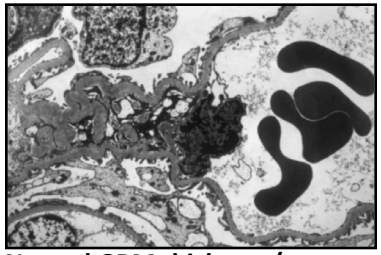

Normal GBM thickness/structure

Normal kidney distribution of collagen IV α1-6 chains

Bowman's capsule

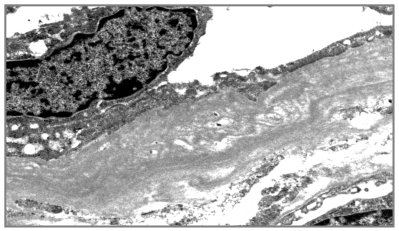

Tubule

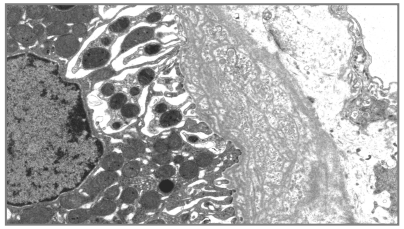

Abnormally thickenned and multilaminated BMs

Renal manifestations

(1) Multicystic kidney disease

(2) Hematuria

(3) CKD

- Only few cases identified with CKD progression
- Associated with multicystic kidney phenotype
- Inconstant proteinuria, only if eGFR<50
- ESRD reached after 50 years

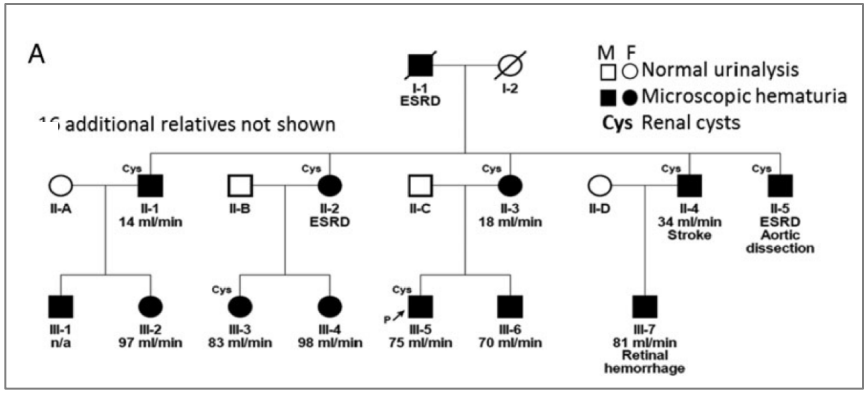

COL4A1 c.4611_4612insG - p.T153fs

Gale et al, NDT, 2015

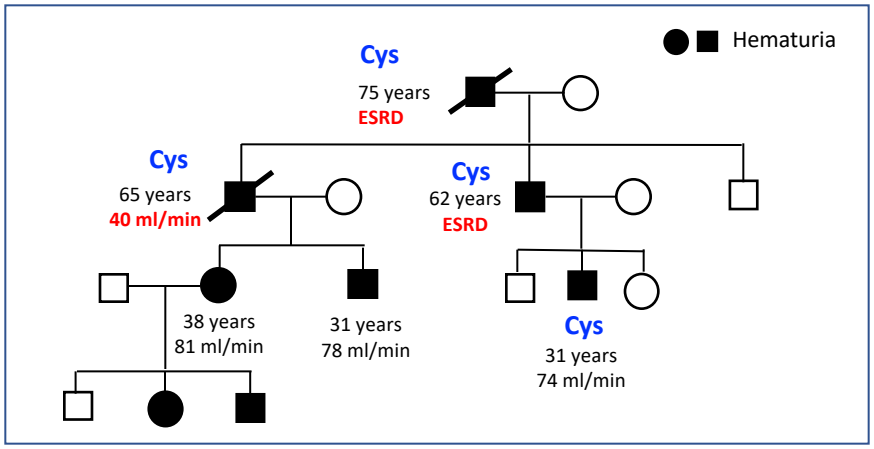

HANAC - *COL4A1* c.1493G>T p.Gly598Val

Plaisier E, NEJM, 2007
Plaisier E, Am J Med Genet, 2010
Gale DP, NDT, 2015

Renal manifestations

(1) Multicystic kidney disease

(2) Hematuria

(3) CKD

(4) Others : exceptionnal…***incidental findings***?

- Unilateral renal agenesis
- Hydronephrosis

Syndromic/ Non-syndromic - COL4A1-related diseases

Syndromic Cerebral small vessel disease

- **Severe neurological presentation +++**
  - Antenatal cerebral haemorrhages
  - Porencephaly
  - Unique or recurrent stoke before 50 years of age
  - Complex epilepsy…
- Variable association
  - Ocular defects
  - +/- **non progressive hematuria**, CK elevation
  - Cerebral aneurysms

HANAC - *Hereditary Angiopathy, Nephropathy, Aneurysms and Cramps*

- **Retinal arteriolar tortuosity**
- **Muscle cramps**
- **Multicystic kidney disease +/- hematuria +/- CKD/ESRD**
- Pauci-symptomatic vascular brain disease
- Raynaud phenomena, supraventricular arrhythmia

Non syndromic forms

- Congenital cataracts
- Microphtalmia
- Retinal arteriolar tortuosity
- Cerebral small vessel disease

Meuwissen ME, Genet Med, 2015
Plaisier E, GeneReviews, 2016
Zagaglia D, Neurology, 2018

Syndromic/ Non-syndromic - COL4A1-related diseases

Syndromic Cerebral small vessel disease

- **Severe neurological presentation +++**
  - Antenatal cerebral haemorrhages
  - Porencephaly
  - Unique or recurrent stoke before 50 years of age
  - Complex epilepsy…
- Variable association
  - Ocular defects
  - +/- **non progressive hematuria**, CK elevation
  - Cerebral aneurysms

HANAC - *Hereditary Angiopathy, Nephropathy, Aneurysms and Cramps*

- **Retinal arteriolar tortuosity**
- **Muscle cramps**
- **Multicystic kidney disease +/- hematuria +/- CKD/ESRD**
- Pauci-symptomatic vascular brain disease
- Raynaud phenomena, supraventricular arrhythmia

Non syndromic forms

- Congenital cataracts
- Microphtalmia
- Retinal arteriolar tortuosity
- Cerebral small vessel disease

Meuwissen ME, Genet Med, 2015
Plaisier E, GeneReviews, 2016
Zagaglia D, Neurology, 2018

Syndromic/ Non-syndromic - COL4A1-related diseases

Syndromic Cerebral small vessel disease

- **Severe neurological presentation +++**
  - Antenatal cerebral haemorrhages
  - Porencephaly
  - Unique or recurrent stoke before 50 years of age
  - Complex epilepsy…
- Variable association
  - Ocular defects
  - +/- **non progressive hematuria**, CK elevation
  - Cerebral aneurysms

HANAC - *Hereditary Angiopathy, Nephropathy, Aneurysms and Cramps*

- **Retinal arteriolar tortuosity**
- **Muscle cramps**
- **Multicystic kidney disease +/- hematuria +/- CKD/ESRD**
- Pauci-symptomatic vascular brain disease
- Raynaud phenomena, supraventricular arrhythmia

Non syndromic forms

- Congenital cataracts
- Microphtalmia
- Retinal arteriolar tortuosity
- Cerebral small vessel disease

Meuwissen ME, Genet Med, 2015
Plaisier E, GeneReviews, 2016
Zagaglia D, Neurology, 2018

Genetic characteristics - COL4A1-related diseases

Genetic characteristics - COL4A1-related diseases

88 *COL4A1* pathogenic variants

- Frameshift : 5
- Splice Site : 5
- **Missense : 77 (87.4%) with 67 Gly substitution***

Meuwissen ME, Genet Med, 2015
Plaisier E, GeneReviews, 2016
Zagaglia D, Neurology, 2018

Genetic characteristics - COL4A1-related diseases

88 *COL4A1* pathogenic variants

- Frameshift : 5
- Splice Site : 5
- **Missense : 77 (87.4%) with 67 Gly substitution***

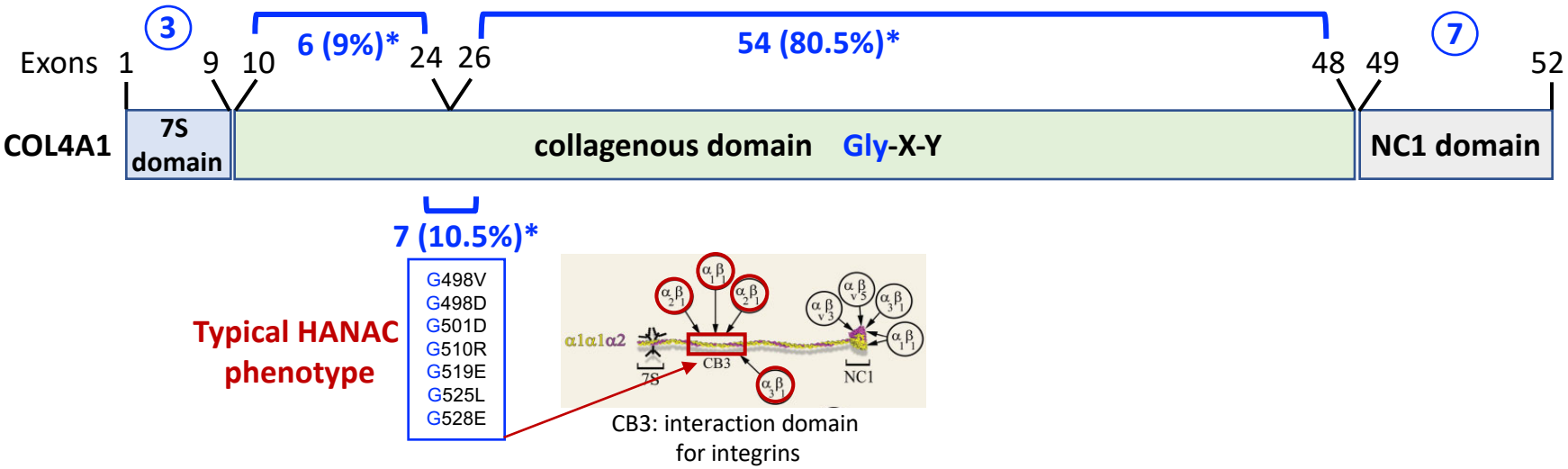

Meuwissen ME, Genet Med, 2015
Plaisier E, GeneReviews, 2016
Zagaglia D, Neurology, 2018

Genetic characteristics - COL4A1-related diseases

88 *COL4A1* pathogenic variants

- Frameshift : 5
- Splice Site : 5
- **Missense : 77 (87.4%) with 67 Gly substitution***

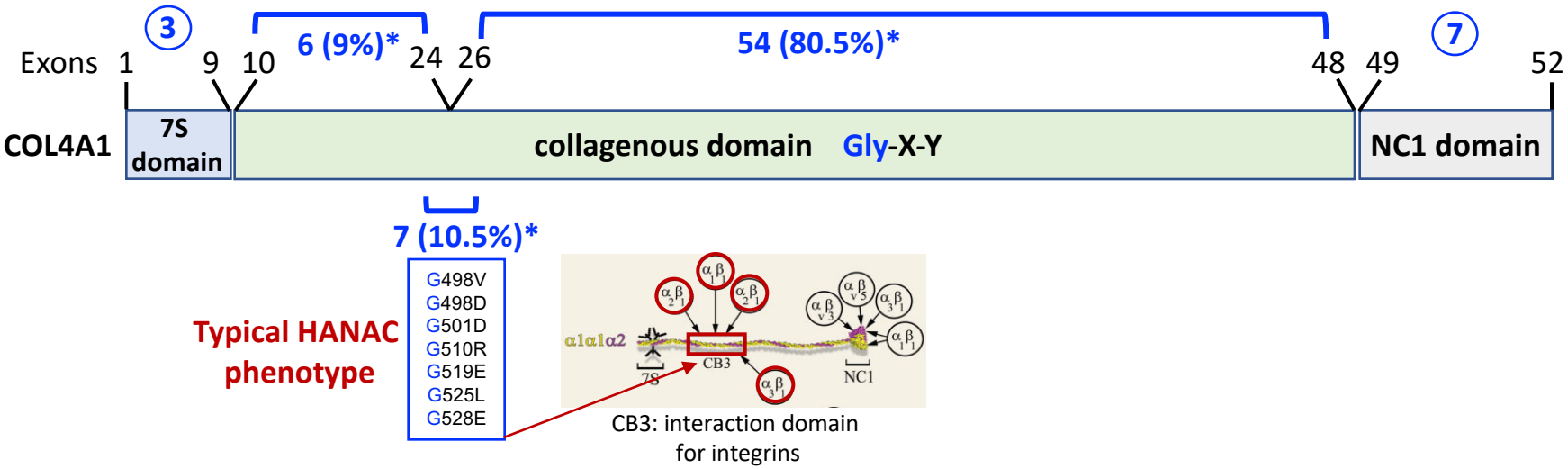

Phenotypic variability : Modifier genes ? environnemental factors?

Meuwissen ME, Genet Med, 2015
Plaisier E, GeneReviews, 2016
Zagaglia D, Neurology, 2018

Inherited *COL4A1* diseases
Diagnostic approach for the nephrologist

Hematuria
Multicystic kidney disease

Search for :

- Neurological event <50 years
- Muscle cramps
- Migraine
- Episodes of transient visual loss
- Familial context

Neurological examination

Brain magnetic resonance imaging

Fundoscopic examination

Renal ultrasound, urine analysis, eGFR

Serum creatine kinase measurement

Extra-renal manifestation(s)
+/-
familial context

+/- negative genetic tests for ADPKD or Alport

***COL4A1* gene screening**

Meuwissen ME, Genet Med, 2015
Plaisier E, GeneReviews, 2016

Differential diagnoses

Inherited cerebral small vessel diseases

CADASIL, CARASIL, HERNS

Autosomal dominant retinal vasculopathy with cerebral leukodystrophy

Inherited anterior eye dysgenesis

> 70 genes

No associated renal defect

Autosomal dominant polycystic kidney disease

Alport's syndrome

Inherited *COL4A1* diseases
Management

Meuwissen ME, Genet Med, 2015
Gould DB, NEJM, 2006
McONeil Plancher J, Case Report Neurol 2015
Plaisier E, GeneReviews, 2016

- **Investigated the extend of the disease at diagnosis**
- **Follow-up according to organ defects**
- **Symptomatic therapy :** antiepileptic drugs, eye surgery
- **Prevention measures to reduce the risk of stroke**
  - Avoid anticoagulant therapy/ aspirin
  - Treatment of hypertension
  - Smoking cessation
  - Avoid situations with an increase risk of head trauma
- **Pregnancy:**
  - Fetal brain imaging
  - Discuss caesarean delivery to prevent brain injury due to birth trauma in newborns
- **Gene counselling for the patient and relatives**
  - Discuss prenatal testing/preimplantation genetic diagnosis in case of history of antenatal brain haemorrhages

Inherited *COL4A1* diseases

Multisystemic disease with important phenotypic variability

Prognosis linked to the cerebral complications

- Primary prevention of brain haemorrhages
- Discuss prenatal testing/preimplantation genetic diagnosis

Kidney disease

- **Multicystic kidney disease**
  - *COL4A1* in NGS panels of ADPKD
  - Not usually benign in case of = long-term FU required
- **A cause au AD familial hematuria**
  - Search for suggestive extrarenal manifestations
  - NGS panels COL4A1 / A3/A4/A5

Save the date

Next Webinar March 21, 2019

ERKNet

The European
Rare Kidney Disease
Reference Network

APOL1 risk genotype in FSGS and other nephropathies

Dr Aude Servais

Department of Adult Nephrology
Necker Hospital
Paris – France

Save the date

Next Webinar March 21, 2019

ERKNet

The European
Rare Kidney Disease
Reference Network

Thank you very much for your attention!

APO **nies**

Dr Aude Servais

Department of Adult Nephrology
Necker Hospital
Paris – France