

# An international consensus approach to the management of atypical hemolytic uremic syndrome in children

Chantal Loirat • Fadi Fakhouri • Gema Ariceta • Nesrin Besbas • Martin Bitzan • Anna Bjerre • Rosanna Coppo • Francesco Emma • Sally Johnson • Diana Karpman • Daniel Landau • Craig B Langman • Anne-Laure Lapeyraque • Christoph Licht • Carla Nester • Carmine Pecoraro • Magdalena Riedl • Nicole C. A. J. van de Kar • Johan Van de Walle • Marina Vivarelli • Véronique Frémeaux-Bacchi • for HUS International

Received: 12 July 2014 / Revised: 26 January 2015 / Accepted: 16 February 2015 / Published online: 11 April 2015  
© IPNA 2015

**Abstract** Atypical hemolytic uremic syndrome (aHUS) emerged during the last decade as a disease largely of complement dysregulation. This advance facilitated the development of novel, rational treatment options targeting terminal complement activation, e.g., using an anti-C5 antibody (eculizumab). We review treatment and patient management issues related to this therapeutic approach. We present consensus clinical practice recommendations generated by HUS International, an international expert group of clinicians and basic scientists with a focused interest in HUS. We aim to

address the following questions of high relevance to daily clinical practice: Which complement investigations should be done and when? What is the importance of anti-factor H antibody detection? Who should be treated with eculizumab? Is plasma exchange therapy still needed? When should eculizumab therapy be initiated? How and when should complement blockade be monitored? Can the approved treatment schedule be modified? What approach should be taken to kidney and/or combined liver–kidney transplantation? How should we limit the risk of meningococcal infection under

C. Loirat (✉)  
Assistance Publique-Hôpitaux de Paris, Hôpital Robert Debré,  
Department of Pediatric Nephrology, Université Paris Diderot  
Sorbonne Paris Cité, Paris, France  
e-mail: chantal.loirat@rdb.aphp.fr

F. Fakhouri  
Centre Hospitalier Universitaire de Nantes, Department of  
Nephrology and Immunology, ITUN and INSERM UMR S-1064,  
Nantes, France

G. Ariceta  
Pediatric Nephrology, Vall d'Hebron Hospital, Autònoma University  
of Barcelona, Barcelona, Spain

N. Besbas  
Department of Pediatric Nephrology, Hacettepe University Faculty  
of Medicine, Ankara, Turkey

M. Bitzan  
Division of Nephrology, Montreal Children's Hospital and McGill  
University, Montreal, Canada

A. Bjerre  
Department of Pediatrics, Oslo University Hospital, Rikshospitalet,  
Oslo, Norway

R. Coppo  
City of the Health and the Science of Turin Health Agency, Regina  
Margherita Children's Hospital, Turin, Italy

F. Emma • M. Vivarelli  
Bambino Gesù Children's Hospital, Rome, Italy

S. Johnson  
Department of Paediatric Nephrology, Great North Children's  
Hospital, Newcastle Upon Tyne, UK

D. Karpman  
Department of Pediatrics, Clinical Sciences, Lund University,  
Lund, Sweden

D. Landau  
Soroka University Medical Center, Beer Sheva, Israel

C. B. Langman  
The Ann and Robert H. Lurie Children's Hospital of Chicago,  
Feinberg School of Medicine, Northwestern University, Chicago, IL,  
USA

A.-L. Lapeyraque  
Service de Néphrologie, Département de Pédiatrie, CHU  
Sainte-Justine, Université de Montréal, Montréal, Canada

complement blockade therapy? A pressing question today regards the treatment duration. We discuss the need for prospective studies to establish evidence-based criteria for the continuation or cessation of anticomplement therapy in patients with and without identified complement mutations.

**Keywords** Anti-factor H antibody · Atypical hemolytic uremic syndrome · Children · Combined liver–kidney transplantation · Complement · Eculizumab · Hemolytic uremic syndrome · Kidney transplantation · Plasma exchange · Plasma infusion · Thrombotic microangiopathy

## Introduction

Major progress has been made since the early 2000s in the understanding of the pathophysiology of atypical hemolytic uremic syndrome (aHUS) and its treatment. In under a decade, complement alternative pathway (AP) dysregulation has emerged as the major cause of aHUS, responsible for 60–70 % of cases [1–4]. In addition, clinical characteristics and patient outcomes have been described and genotype-phenotype correlations established. This new knowledge has contributed to a more precise definition of aHUS, a term now preferentially reserved for hemolytic uremic syndrome (HUS) without coexisting disease [3–8]. The genetic background of aHUS continues to unfold, and as an example, recently identified mutations in the gene encoding diacylglycerol kinase  $\epsilon$  (DGKE) [9] suggest that complement-independent forms of aHUS exist. Plasma therapy was the mainstay of treatment for aHUS until 2009, although controlled trials were lacking. The

guideline for the investigation and initial therapy in aHUS published by the European Pediatric Study Group for HUS in 2009, based on anecdotal case reports, retrospective series and expert consensus, advocated early, frequent and high-volume plasma exchanges (PE) [10]. The recently published audit of this guideline indicated considerable morbidity associated with plasma therapy in children [11]. Since 2009, four prospective trials and over 80 case reports have demonstrated that effective terminal complement blockade with eculizumab can rescue native kidney function or allow successful kidney transplantation after renal loss due to aHUS [12–14]. Here we propose a diagnostic and therapeutic approach for pediatric patients with aHUS in 2014. The availability of the first effective anti-complement therapeutic agent, eculizumab, has dramatically changed the outlook of this often-dismal disease. However, its use in clinical practice raises important questions, such as who should receive the drug, when to start such therapy, and is it safe to stop treatment once the disease is controlled. We are aware of the limitations of our recommendations in a world where clinician experience, diagnostic tools, and eculizumab availability vary between centers and countries.

## The definition of atypical HUS

Our group favors an etiology and pathophysiology-based classification of the various forms of thrombotic microangiopathies (TMA) (Fig. 1) [4–8, 15–19]. Thrombotic thrombocytopenic purpura (TTP) is caused by a severe deficiency (<10 %) in ADAMTS13 (A Disintegrin And Metalloproteinase with a ThromboSpondin type 1 motif, member 13) activity, either due to congenital absence of functional protein or to the presence of acquired anti-ADAMTS13 antibodies, requiring different and specific therapies. ADAMTS13 deficiency-associated TTP should no longer be classified as a variant of aHUS, but as a differential diagnosis that has to be ruled out in patients suspected to have aHUS. Similarly, HUS caused by Shiga toxin (Stx) producing *Escherichia coli* (STEC) infection and other specific infectious agents must be excluded before aHUS is diagnosed. However, until recent years, the aHUS acronym has been used variably to designate only HUS without a coexisting disease/condition, or any HUS not associated with severe ADAMTS13 deficiency or STEC infection. This latter use of the term has resulted in the inclusion of “secondary” cases better explained by coexisting disease within aHUS cohorts. Illustrating this definitional heterogeneity, one of the two series that analyzed phenotype–genotype correlations in aHUS patients included both secondary (17 % of cases) and non-secondary forms of HUS [1], while the other included only non-secondary forms [3]. The currently used definition is based on the emerging agreement among hematologists and nephrologists that the term aHUS should be

C. Licht

The Hospital for Sick Children, Toronto, Canada

C. Nester

Departments of Internal Medicine and the Stead Family Department of Pediatrics, University of Iowa, Iowa City, Iowa, USA

C. Pecoraro

Santobono Children's Hospital, Naples, Italy

M. Riedl

Department of Pediatrics, Innsbruck Medical University, Innsbruck, Austria

N. C. A. J. van de Kar

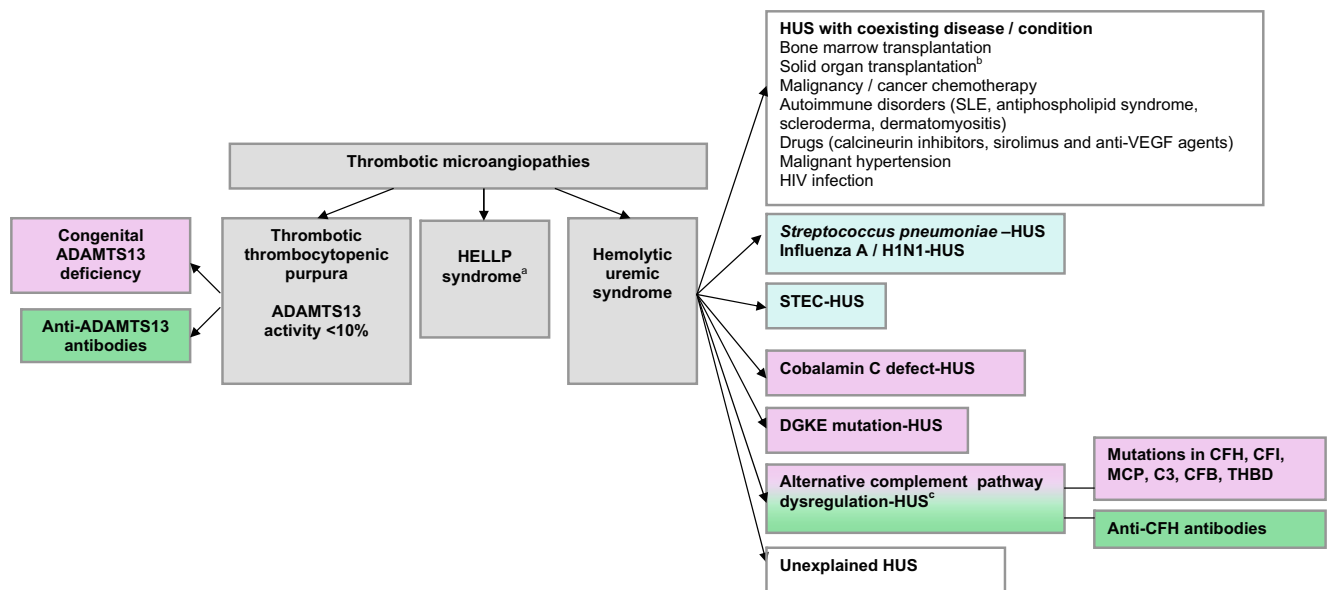
Department of Pediatric Nephrology, Amalia Children's Hospital, Radboud University Medical Center, Nijmegen, The Netherlands

J. Van de Walle

University Hospital Ghent, Ghent, Belgium

V. Frémeaux-Bacchi

Assistance Publique-Hôpitaux de Paris, Hôpital Européen Georges Pompidou, Laboratory of Immunology, INSERM UMRS 1138, Paris, France



**Fig. 1** An etiology-based classification of the various forms of thrombotic microangiopathies. Approximately one-third of women with HELLP syndrome have a complement mutation [17]. Thirty percent of patients with de novo post-kidney transplant HUS have a complement mutation [18]. Eighty-six percent of women who have the first episode of HUS during pregnancy (mostly in the post-partum) have a complement mutation. Therefore, pregnancy-HUS is classified as alternative complement pathway dysregulation-aHUS [19] —Post-infectious —Hereditary —Autoimmune. ADAMTS13: A Disintegrin And

Metalloproteinase with a Thrombospondin type 1 motif, member 13; CFB: complement factor B; CFH: complement factor H; CFI: complement factor I; DGKE: diacylglycerol kinase  $\epsilon$ ; HELLP: hemolysis, elevated liver enzymes, and low platelet count syndrome; HIV: human immunodeficiency virus; HUS: hemolytic uremic syndrome; MCP: membrane cofactor protein (CD46); SLE: systemic lupus erythematosus; STEC: Shiga toxin-producing *Escherichia coli*; THBD: thrombomodulin; VEGF: vascular endothelium growth factor

reserved for patients with HUS without coexisting disease [4–8]. There is an ongoing debate whether or not to limit the term aHUS to cases with dysregulation of the AP of complement secondary to complement gene mutations or anti-complement factor H (CFH) antibodies. At present, definitive exclusion or confirmation of a complement-related genetic defect is time consuming and not ubiquitously possible. The following discussion and recommendations will therefore focus on the clinical management of children with aHUS without coexisting disease or specific infection as defined above.

## Diagnosis of atypical HUS

Biological assays to confirm the clinical diagnosis of aHUS

In children, clinical presentation and baseline laboratory results usually allow the diagnosis of *Streptococcus pneumoniae*, STEC and cobalamin C (cblC) defect-HUS or of TTP with a good degree of certainty to inform adequate treatment initiation (Table 1) [20–34]. Figure 2 outlines confirmatory investigations for each of the common differential diagnoses [35–47].

Commonly used ADAMTS13 activity assays are based on the signal-inducing cleavage by plasma ADAMTS13 of the

von Willebrand Factor (VWF) substrate peptide containing the specific cleavage and recognition site for VWF (Fret-VWF 73). These are commercially available and relatively easy to establish and give results within a few hours [40]. Results of different commercial kits show reasonable agreement with Fret-VWF73, with 80–90 % concordance [41, 42]. STEC infection should always be ruled out as soon as possible when aHUS is suspected, using stool culture and fecal PCR or immunologic assay for Stx [48]. In more than one-third of children with aHUS, diarrhea/gastroenteritis is the apparent trigger of onset. Initial biological sampling in any child with suspected aHUS, whatever their age, should include testing (available in most university hospitals) for cblC defect (Fig. 2). Cases presenting with aHUS that are rescued by hydroxocobalamin treatment appear to be at least as frequent in late-onset cblC defect as in neonatal forms [29–34] (Table 1).

## Complement investigations in aHUS

Sixty to 70 % of aHUS patients carry currently identifiable mutations in complement genes or anti-CFH antibodies that result in the loss of protection of endothelial cells and platelets from complement attack and ultimately in TMA lesions [4, 49]. Table 2 summarizes the various complement anomalies demonstrated in two large series comparing children and

**Table 1** Clinical characteristics at onset and first-line treatment of children with various forms of HUS and TTP

	<i>S. pneumoniae</i> -HUS [20]	Congenital TTP [21–23]	Acquired TTP [21, 22, 24, 25]	STEC-HUS [26–28]	CbIC defect-HUS [29–34]	aHUS [3]
Age, years	<2	Birth (neonatal jaundice)	<2: ~15 % 2–<9: ~20 % 9–16: ~60 %	<0.5: ~5 % 0.5–3: ~65 % >3: ~30 %	<0.1: ~50 % 1.5–14: ~40 % ≥20: ~10 %	Birth to 0.5: 28 % 0.5 to 2: 28 % 2–15: 44 % 39 %
Diarrhea, %	No	Possible	Possible	95 % Bloody diarrhea ≥60 % No	Possible in neonatal forms +vomiting, poor sucking, failure to thrive Common	Possible
Progressive onset, %	Sudden severe infection: pneumonia ~70 % meningitis ~30 % bacteremia ~80 %	Possible (isolated thrombocytopenia)	Possible	No	Common	Possible
Hematological characteristics, %	Positive DAT (direct Coombs) ~90 % Elevated WBC count	Platelets generally <30G/L	Platelets generally <30G/L	Platelets often >30G/L Elevated WBC count frequent	Megaloblastosis Leukocytopenia Pancytopenia	Platelets generally >30G/L, >150G/L in 15 %; Hemoglobin >10 g/dl in 6 %
Acute renal failure, %	100 %, dialysis required in 40 to 80 %	Uncommon and mild, no dialysis required <sup>a</sup>	Uncommon and mild, dialysis rarely required <sup>a</sup>	95 %, dialysis required in ~50 %	Proteinuria/hematuria/HT/ Progressing mild to moderate CKD±acute episodes in ~50 % 100 % in neonatal forms (lethargy, hypotonia, seizures) + retinopathy	85 %, dialysis required in 60 % 16 %
Neurological symptoms <sup>b</sup> , %	Meningitis in ~30 %	~35 %	~70% <sup>b</sup>	~20 %	Psychiatric symptoms, cognitive impairment frequent in late forms	2 %
Cardiac involvement <sup>c</sup> , %	Possible	Possible	Possible	2–5 %	55 % in neonatal forms PAH in 60 % of late forms	27 % (years apart) Autosomal dominant (with variable penetrance) or recessive inheritance
Familial history of the disease	No	Autosomal recessive inheritance (siblings with TTP)	No	Simultaneous occurrence or a few days–weeks apart (person-to-person)	Autosomal recessive inheritance (siblings with the disease)	Autosomal dominant (with variable penetrance) or recessive inheritance
First-line treatment	Vancomycin + extended spectrum cephalosporin FP and unwashed PRBC /platelets traditionally avoided <sup>d</sup>	FP infusion	PE + corticosteroids ± rituximab	Supportive treatment <sup>e</sup>	Parenteral hydroxocobalamin with oral folic acid and betaine	Ecilizumab (PE if ecilizumab is not available)

aHUS: atypical hemolytic uremic syndrome; CKD: chronic kidney disease; CNS: central nervous system; DAT: direct agglutination test; FP: frozen plasma; HUS: hemolytic uremic syndrome; HT: hypertension; N: number; ND: not documented; PAH: pulmonary arterial hypertension; PE: plasma exchange; PI: plasma infusion; PRBC: packed red blood cells; STEC: Shiga toxin-producing *Escherichia coli*; TTP: thrombotic thrombocytopenic purpura; WBC: white blood cell  
% percentage of patients

Number in brackets: reference number

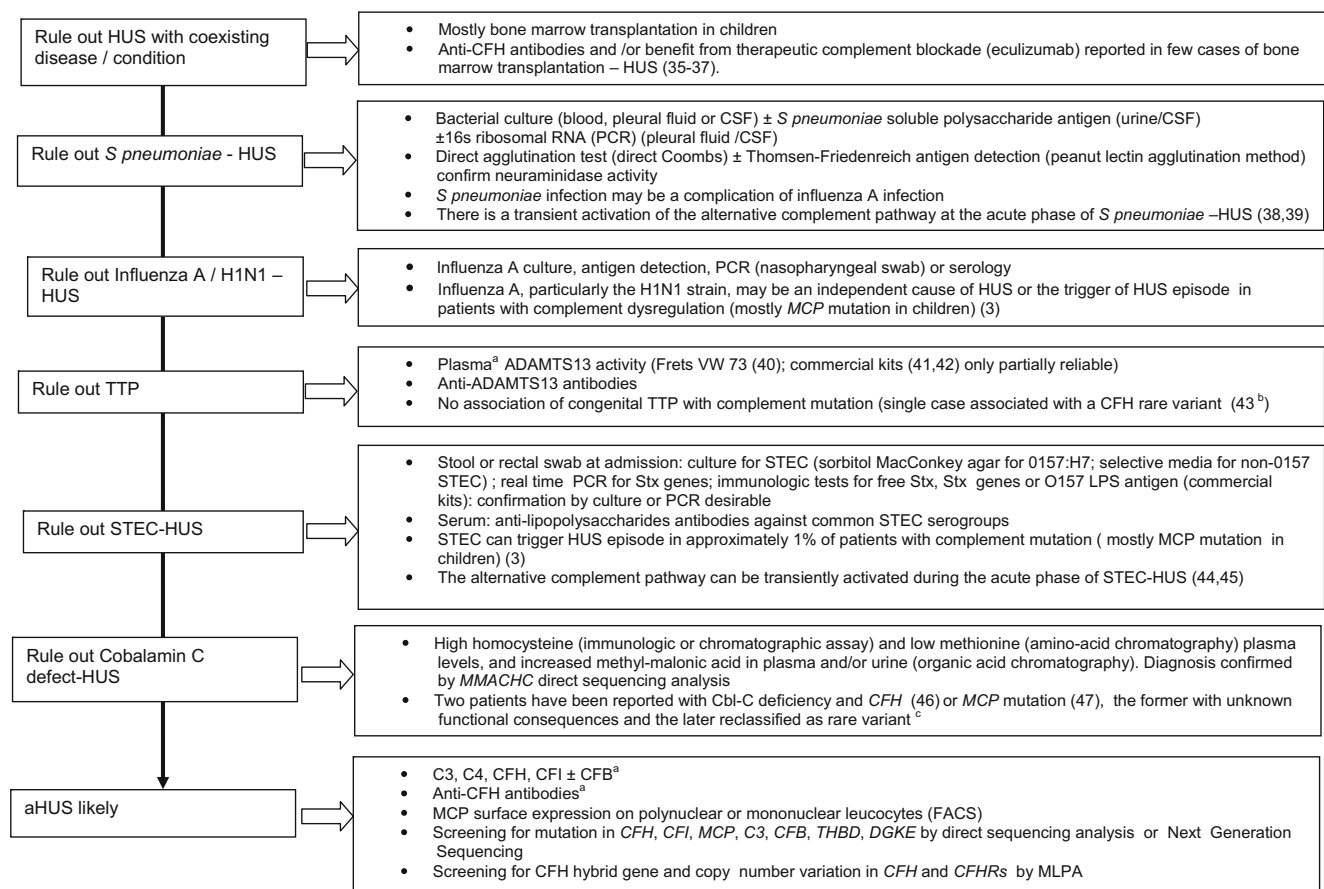
<sup>a</sup>Transient hematuria, hemoglobinuria, proteinuria with normal or slightly elevated serum creatinine level are frequent during acute episodes, but acute renal failure is rare

<sup>b</sup>Headaches, altered mental status, visual problems, paresis, seizures, coma. The higher frequency of neurological manifestations in acquired TTP may be partly explained by the high frequency of headaches (36 % of patients in [21]), a symptom not analyzed in young children with congenital TTP

<sup>c</sup>Scarcely documented in all subgroups

<sup>d</sup>Anti-Thomsen-Friedenreich antibodies present in FP: FP and unwashed blood products may aggravate HUS

<sup>e</sup>Ecilizumab is prescribed in some countries for patients with brain/cardiac/multivisceral involvement. Further studies are required to establish the benefit of complement blockade treatment in STEC-HUS



**Fig. 2** Diagnostic algorithm for atypical HUS in children **a)** Blood sampling imperatively before plasma exchange/plasma infusion **b)** Communication of M. Noris, Bergamo, Italy **c)** Communication of author V. Fremeaux-Bacchi. ADAMTS13: A Disintegrin And Metalloproteinase with a ThromboSpondin type 1 motif, member 13; aHUS: atypical hemolytic uremic syndrome; Cbl-C: cobalamin C; CFB: complement factor B; CFH: complement factor H; CFHRs:

complement factor H-related proteins; CFI: complement factor I; CKD: chronic kidney disease; ESRD: end-stage renal disease; CSF: cerebrospinal fluid; DGKE: diacylglycerol kinase  $\epsilon$ ; FACS: Fluorescence Activated Cell Sorting; HUS: hemolytic uremic syndrome; MCP: membrane cofactor protein (CD46); MLPA: multiplex ligation dependent probe amplification; PCR: polymerase chain reaction; STEC: Shiga toxin-producing *Escherichia coli*; Stx: Shiga toxin

adults [1, 3]. Table 3 juxtaposes clinical features described in three subgroups of aHUS with pediatric onset: HUS with/without complement mutation, with anti-CFH antibody or DGKE mutation [3, 9, 50–59]. Most patients with HUS due to a complement mutation carry a heterozygous mutation. Due to variable penetrance, only 20–30 % of patients report a family history of HUS [1, 3].

Homozygous haplotypes (defined by five frequent genetic variants transmitted en bloc) of CFH (CFH tggtg) and membrane cofactor protein (MCP) (MCP ggaac) have been demonstrated to be significantly more frequent in patients with aHUS than in controls. While their role in the degree of penetrance of the disease is likely [59], their influence on the age at onset (pediatric versus adult) has not been demonstrated [3]. Some plasminogen and ADAMTS13 variants may also have a predisposing role [60, 61]. Lastly, 90–95 % of patients with anti-CFH antibodies have a complete deficiency of

CFH-related proteins 1 (CFHR1) and 3 (CFHR3), due to a homozygous deletion of *CFHR1-R3* [50–52, 54, 62], a polymorphism carried by 2–9 % of healthy people of European, 16 % of African, and  $\leq 2$  % of Chinese descent [63].

Recently, mutations in the gene encoding DGKE, a protein of the lipid kinase family, which is expressed in the endothelium, platelets and podocytes, have been identified in an autosomal recessive form of aHUS occurring in the first year of life [9, 56, 57]. The mechanism of HUS is most likely related to the activation of protein kinase C due to the loss of function of DGKE, leading to an upregulation of prothrombotic factors and platelet activation [64]. Whether complement activation is indirectly involved in this form of aHUS, as suggested by decreased C3 levels in four of the 19 patients so far reported (three with an isolated DGKE mutation and one with a combined C3 variant), remains to be demonstrated [9, 56, 57].



**Table 2** Frequency of complement and DGKE abnormalities according to age at onset in atypical HUS

	[3]			[1]		
	Total	Children	Adults	Total <sup>a</sup>	Children <sup>a</sup>	Adults <sup>a</sup>
No. of patients	214	89	125	256	152	104
CFH (%)	27.5	21.3	32	25.3	25.6	25
Homozygous	1.8	4.4	0	4.2		
Heterozygous	25.7	16.8	32	21.1		
MCP (%)	9.3	13.5	6.4	7	9.2	3.8
Homozygous	2.8	5.6	0.8			
Heterozygous	6.5	7.8	5.6			
CFI (%)	8.4	6.7	9.6	3.9	2.6	5.7
C3 (%)	8.4	7.8	8.8	4.6	3.9	5.7
CFB (%)	1.4	1	2.4	0.4		
Anti-CFH antibodies (%)	6.5	11	3.2	3.1	3.9	1.9
THBD (%)	0	0	0	5	7.8	0.9
Combined (%)	4.2	3.4	4.8	3		
Complement-mediated (%)	65.7	64.7	67.2	52.3	53	43
DGKE (%)	3.2	7.9	0			
No identified abnormality (%)	31.1	27.4	32.8	47.7	47	57

CFB: complement factor B; CFH: complement factor H; CFI: complement factor I; DGKE: diacylglycerol kinase  $\epsilon$ ;

MCP: membrane cofactor protein (CD46); THBD: thrombomodulin

<sup>a</sup> Calculated from Table 2 in [1]

% percentage of patients

Empty line: not documented

Number in brackets: reference number

Normal C3, C4, CFH, and CFI plasma levels do not exclude the diagnosis of complement dependent-HUS and decreased C3 level can be observed at the acute phase of STEC-HUS and *S. pneumoniae*-HUS

Decreased C3 levels are observed in only 30–40 % of patients with aHUS [1, 3, 4, 65] (Table 3). Thus, a normal C3 level does not rule out a diagnosis of aHUS. A normal plasma C4 concentration in the presence of a decreased C3 level suggests activation of the complement AP, as would a decreased factor B (CFB) concentration. Decreased CFH or complement factor I (CFI) plasma levels are observed in approximately 50 and 30 % of patients with mutated *CFH* or *CFI*, respectively [3, 16]. Therefore, a normal CFH or CFI plasma level does not exclude a mutation in the corresponding gene.

Recent data suggest that levels of C5a and soluble C5b-9 (sC5b-9) are elevated at the acute phase of aHUS and may be biological markers to differentiate aHUS from TTP [66]. Increased C5a and sC5b-9 plasma levels have been confirmed in approximately half of aHUS patients during the acute phase of the disease and also during remission [67], while another group reported the normalization of complement activation product levels after remission, including sC5b-9 [68]. Thus further confirmation is required before these markers become part of routine clinical care.

Of note, decreased C3 levels [38, 39] and MCP expression (communication from author V. Fremaux-Bacchi, unpublished) may be observed during the acute phase of STEC-HUS and *S. pneumoniae*-HUS (Fig. 2).

Anti-CFH antibody assay: a technique now standardized

All patients with suspected aHUS should be tested for the presence of anti-CFH antibodies on blood samples collected before PE or plasma infusion (PI). A recent publication describes the collaborative effort of 7 European laboratories to standardize the detection and quantification of anti-CFH antibodies using the enzyme-linked immunosorbent assay technique [69]. It is hoped that similar initiatives will follow in other countries [53]. Assay results can be made available within a few days and guide treatment decisions. Anti-CFH antibody titers at the acute phase (1,000–50,000 Arbitrary Units (AU)/ml) (positive threshold 100–150 AU/ml according to values in 50 and 90 normal plasma samples, respectively [50, 52]), are inversely correlated with C3 levels.

Who should undergo genetic screening, when and why?

Genetic screening results are required in all patients for a number of reasons (Box 1). Although ideal, they are not

**Table 3** Clinical characteristics of children with anti-CFH antibody-associated HUS, aHUS with or without complement mutation, or with DGKE mutation

Characteristics	Anti-CFH antibody-associated HUS [50–52] <sup>a</sup>	aHUS with or without complement mutation [3] <sup>b</sup>	aHUS with <i>DGKE</i> mutation [9, 56, 57] <sup>c</sup>
Age at onset, years	Mostly 5–13	<i>CFH</i> and <i>CFI</i> mutation: mostly < 2 <i>MCP</i> mutation: >1, mostly 2–12 <i>C3</i> mutation and no complement mutation identified: any age	All < 1
Low C3 levels, %	40–60 %	Overall: ~30 % Mutation in <i>CFH</i> : 70 %; <i>CFI</i> : 60 %; <i>MCP</i> : 0 %; <i>C3</i> : 70 %; <i>CFB</i> : 100 %; no complement mutation identified: ND	21 % (4/19)
Death, %	9–16 %	8 % (mostly in children < 1 year of age)	None among 19 DGKE-HUS identified. However, family history reported prior death from HUS in two children [56]
ESRD or death, %	~30 % at 3 years	Overall: 17 % at 1 month, 29 % at 1 year, 36 % at 5 years At 1 and 5 years: mutation in <i>CFH</i> : 56 % and 63 %; <i>CFI</i> : 50 %; <i>C3</i> : 43 %; <i>MCP</i> : 0 % and 17% <sup>d</sup> ; No mutation: 23 % and 27 %	7 % at 1 month and up to 5 years CKD Grade 4–5 at 20–25 years [9]
Relapses, %	~60 % without immunosuppression ~10 % with immunosuppression	<i>CFH</i> , <i>CFI</i> , <i>C3</i> mutation and no mutation: 20–40 % <i>MCP</i> mutation: ~80% <sup>d</sup>	~80 % during first 5 years 0 % subsequently [9]
Mutation-associated disease penetrance	NA	Homozygous mutation: 100 % Heterozygous mutation: 50 %	Homozygous mutation: 100 % Heterozygous mutation: 0 %

aHUS: atypical hemolytic uremic syndrome; CFB: complement factor B; CFH: complement factor H; CFI: complement factor I; DGKE: diacylglycerol kinase  $\epsilon$ ; ESRD: end-stage renal disease; MCP: membrane cofactor protein (CD46); NA: not applicable

% percentage of patients

Number in brackets: reference number

<sup>a</sup> References 50, 51, and 52 included 45, 19, and 138 patients with anti-CFH antibody-associated HUS, respectively

<sup>b</sup> Reference 3 included 89 children with aHUS, of whom 49 (55 %) had *CFH*, *CFI*, *MCP*, *C3*, or *CFB* mutations, 10 (11 %) had anti-CFH autoantibodies and 30 (33.7 %) had no complement abnormalities identified

<sup>c</sup> References 9, 56, and 57 included 13, two, and four patients with *DGKE* mutation, respectively. One patient had C3 level just below normal value [9]. Decreased C3 levels were also observed in two siblings with isolated *DGKE* mutation [56] and one patient with an associated C3 variant [57]

<sup>d</sup> The association of homozygous or compound heterozygous *MCP* mutation with common variable immunodeficiency has been reported [58]. Patients with homozygous/compound heterozygous *MCP* mutation should be investigated for immunodeficiency as they may have frequent relapses triggered by infections and require immunoglobulin therapy to prevent infections and thus HUS relapses.

In patients with *MCP* mutation, the presence of mutations in other genes increases the risk of progression to ESRD compared to patients with isolated *MCP* mutation (50 vs. 19 % within 3 years from onset, respectively [59])

available immediately and can therefore not inform immediate therapeutic decisions. Mutations in 6 genes have been associated with increased susceptibility for aHUS (*CFH*, *CFI*, *MCP*, *C3*, *CFB* and *THBD* (thrombomodulin). They should be analyzed by direct sequencing. Combined mutations are found in 3–6 % [2–4, 59] of patients with aHUS. Multiplex ligation-dependent probe amplification (MLPA) is required to detect hybrid CFH genes (5 % of patients) and copy number variations in the genes encoding CFH and CFH-related (CFHRs) proteins [3, 4]. Lastly, screening for DGKE mutation should be performed in children with onset of aHUS before the age of 1–2 years [9, 56, 57], although the age of screening may need to increase if case reports suggest DGKE mutations in older individuals with aHUS.

Next-generation sequencing analysis allows the simultaneous study of all potentially relevant genes. It has the potential to accelerate the diagnostic process and decrease the costs of genetic analysis. The use of exome sequencing, which has been successfully applied to identify HUS-causing mutations in the *DGKE* gene [9] is still limited to research laboratories.

Due to low penetrance of the disease (only 50 % of family members carrying the same complement mutation as the proband will have the disease), genetic screening is not recommended in siblings/family members of a patient with a heterozygous complement mutation. Exceptions include the prospect of living-related kidney donation or of pregnancy.

**When**

- First episode of aHUS: Start genetic screening after confirmation that there is no causative disease, no STEC infection, no severe ADAMTS 13 deficiency and no hyperhomocysteinemia /methyl-malonic aciduria.
- Start genetic screening without delay if
  - Relapse of HUS
  - Familial history of non synchronous HUS
  - Pregnancy/post-partum-HUS
  - De novo post-transplant HUS
- Genetic screening required before kidney transplantation for aHUS. Not justified before transplantation for STEC-HUS, unless this diagnosis was uncertain/unproven.

**Why**

- Genetic characterization necessary for
- Confirmation that the disease is complement-dependent or not
  - Establishing prognosis, risk of relapses and of progression to ESRD
  - Genetic counselling to parents and family
  - Decisions for kidney transplantation: choice of the donor, treatment schedule to prevent or treat post-transplant recurrence, decision of combined kidney-liver transplantation
  - Further prospective studies are required to establish the safety of complement blockade treatment discontinuation, according to the genetic background

**Box 1** Genetic testing of patients with atypical HUS - Indications and strategies. ADAMTS13: A Disintegrin And Metalloproteinase with a Thrombospondin type 1 motif, member 13; aHUS: atypical hemolytic

uremic syndrome; ESRD: end-stage renal disease; HUS: hemolytic uremic syndrome

Should patients with anti-CFH antibodies be screened for complement mutations?

This question has been raised after Moore et al. reported sequence variants in complement genes in five of 13 patients with anti-CFH antibody-associated HUS [62]. In another series, no complement mutation was found in 26 patients with anti-CFH antibody-associated HUS [50]. The current recommendation is to perform genetic analyses even when anti-CFH antibodies are present. If a mutation is identified in a patient with anti-CFH antibodies, the therapeutic management should be decided on a case-by-case basis, depending on the antibody titer and the functional consequences of the mutation.

### Treatment options in the pre-complement blockade treatment era

Plasma exchange/plasma infusion: uncertain benefit and a high rate of technique-related complications in children

The European Pediatric Study Group for HUS published a guideline in 2009 advocating early (within 24 h) and intensive PE during the first month of diagnosis [10]. A recent audit of the effects of this guideline analyzing 71 patients treated for aHUS between 1 July 2009 and 31 December 2010 in

European or North American university hospitals [11] revealed that 51 children received plasma therapy through a central venous catheter. Sixteen children (31 %) experienced 17 catheter-related complications (infection in eight, thrombosis/ischemia in four, hemorrhage in two, chylothorax in one). Eight patients became sensitized to plasma components leading to therapy withdrawal in one case. This confirmed that despite technical improvements in the procedure, PE in children continues to be fraught with complications. Although the audit was not designed to measure treatment efficacy, outcome at day 33 suggested limited efficacy of plasma therapy on renal outcome [11]. A dozen case reports—mostly of children with CFH mutations—showed that early plasma therapy, generally consisting of daily PE until platelet count, hemolysis and lactate dehydrogenase (LDH) level normalized and renal function improved, followed by maintenance PE/PI, could prevent relapses and preserve renal function at follow-up, for up to 6 years [5, 16, 48]. However, although plasma therapy allowed complete or partial remission (hematologic remission with renal sequelae) in 78 % of aHUS episodes in children and 53 % in adults in the Italian cohort, 48 % of children and 67 % of adults had died or reached end-stage renal disease (ESRD) at 3-year follow-up [1]. Progression to ESRD during the first episode of aHUS was similar in children and adults with CFH mutation who received high-intensity plasma therapy compared to those



who did not [3]. The benefit of PE/PI in DGKE-HUS is uncertain [9, 56, 57].

### Kidney transplantation

The overall rate of post-transplant recurrence in aHUS in the pre-C5 blockade therapy era was 60 % [1, 70] and graft survival was 30 % at 5 years follow-up in patients with recurrence compared to 68 % in those without recurrence [70]. Forty-three percent of recurrences occurred during the first month and 70 % within the year after transplantation. Eighty percent of patients who had lost a prior graft from recurrence had recurrence after re-transplantation. The predominant independent risk factor for recurrence was the presence of a complement mutation. The risk was highest (approximately 80 %) in patients with *CFH*, *C3* or *CFB* mutations, and approximately 50 % in patients with *CFI* mutation, compared to approximately 20 % in patients with no identified complement mutation [70]. The risk of post-transplant recurrence in patients with *MCP* mutation has been shown to be low (<10 %) if the mutation was isolated (the graft expresses the non-mutated MCP protein), while it was approximately 30 % if the *MCP* mutation was associated with a *CFH*, *CFI*, or *C3* mutation [59]. No post-transplant recurrence has been observed to date in three patients with DGKE mutation [9]. The recurrence risk is low in anti-*CFH* antibody-associated HUS if the antibody titer is low (<500–1,000 AU/ml) at the time of transplantation, while substantial if elevated [50, 54, 62, 71, 72]. One patient with a *THBD* mutation has been reported to have post-transplant recurrence [73].

PE/PI for post-transplant recurrence generally failed to prevent graft loss [1, 70]. Therefore prophylactic PE/PI (started just before transplantation) was recommended [74]. The efficacy of this strategy is not well documented. However, nine patients who received prophylactic PE/PI had a significantly higher graft survival rate free of recurrence than 62 patients without prophylactic PE/PI [70].

### Terminal complement blockade treatment

Ecuzumab, a monoclonal humanized anti-C5 antibody, prevents C5 cleavage and the formation of C5a and C5b-9, thus blocking the C5a pro-inflammatory and the C5b-9 pro-thrombotic consequences of complement activation [12]. We are aware of approximately 180 aHUS patients treated with ecuzumab reported in the literature, including 100 patients treated within four prospective, open-label, single-arm trials conducted by Alexion Pharmaceuticals. Ecuzumab is approved for the treatment of aHUS in many countries, including the European Union and the USA [75, 76]. Recommended dosing regimen is indicated in Table 4.

**Table 4** Recommended ecuzumab dosing regimen for patients with atypical HUS (aHUS)

Patient body weight	Induction regimen	Maintenance regimen
40 kg and over	900 mg weekly x 4 doses	1,200 mg at week 5; then 1,200 mg every 2 weeks
30 kg to less than 40 kg	600 mg weekly x 2 doses	900 mg at week 3; then 900 mg every 2 weeks
20 kg to less than 30 kg	600 mg weekly x 2 doses	600 mg at week 3; then 600 mg every 2 weeks
10 kg to less than 20 kg	600 mg weekly x 1 dose	300 mg at week 2; then 300 mg every 2 weeks
5 kg to less than 10 kg	300 mg weekly x 1 dose	300 mg at week 2; then 300 mg every 3 weeks

The listed dosing regimen is from the product label [75, 76] specified by the manufacturer. Dosing intervals are based on pharmacokinetic studies and should be kept within 2 days of the recommended time points

As plasma exchange clears the drug from the circulation, supplemental dosing is required in case of concomitant plasma exchange [75, 76]

### Prospective trials of ecuzumab in patients with aHUS

Table 5 summarizes the trials' designs, inclusion/exclusion criteria and the patients' baseline characteristics, and Table 6 provides the primary efficacy endpoints and results [13, 77–81]. Results of the first two trials are published [13, 77]. Only preliminary data are available for the subsequent trials (Abstracts, [78–81]).

In trial 1 comprising 17 adult and adolescent patients with persistent TMA resistant to PE/PI, platelet count normalized 7 days (median; range, 1–218 days) and LDH activity 14 days (range, 0–56 days) after the first dose of ecuzumab. Remission of hematological disease activity (platelet count, cessation of hemolysis; see definition in Table 6) was maintained over the duration of the treatment (median 2 years) in 88 % of patients. The estimated glomerular filtration rate (eGFR) improved by 32 ml/min/1.73 m<sup>2</sup> (95 % confidence interval (CI) 14–49 ml/min/1.73 m<sup>2</sup>) at 26 weeks ( $p=0.001$  versus baseline eGFR). The gain in eGFR was maintained over the treatment period. The extent of eGFR improvement correlated with shorter time to ecuzumab initiation ( $p=0.009$ ). Only 12 % of patients (2/17) received chronic dialysis after a median of 2 years treatment duration [13, 77]. Gains in eGFR were less in transplanted than in non-transplanted patients ( $14.8 \pm 18.7$  ml/min/1.73 m<sup>2</sup> versus  $48.3 \pm 38.4$ ), but earlier treatment initiation correlated with greater gain in eGFR in transplanted similar to non-transplanted patients [78]. In trial 2 comprising 20 adult and adolescent patients with chronic kidney disease (CKD) who switched to ecuzumab after long-term PE/PI, 95 % of patients maintained hematologic remission and

**Table 5** Study design, key inclusion and exclusion criteria and baseline patients' characteristics in 4 prospective, open-label, single-arm, non-randomized, multinational trials of the efficacy of eculizumab in atypical HUS (aHUS)

	Trial 1	Trial 2	Trial 3	Trial 4
	Adults/adolescents with progressing TMA despite PE/PI ( $n=17$ ) [13, 77]	Adults/adolescents with long disease duration and CKD under long-term PE/PI ( $n=20$ ) [13, 77]	Children Early initiation ( $n=22$ ) [79]	Adults Early initiation ( $n=41$ ) [80]
Study design	Screening period $\leq 3$ days, then PE/PI stopped and eculizumab initiated, 26-week treatment period followed by a long-term extension.	Screening period $\leq 2$ weeks, then 8-week observation period, then PE/PI stopped and eculizumab initiated, 26-week treatment period followed by a long-term extension.	Screening period 0–7 days, then PE/PI (if any) stopped and eculizumab initiated, 26-week treatment period followed by a long-term extension.	
Key inclusion criteria	Age $\geq 12$ years Progressing TMA measured by platelet count $<150\text{G/L}$ and a decrease of $>25\%$ lower than the average of 3 platelet counts before the most recent HUS manifestation, despite $\geq 4$ PE/PI in the week before screening Evidence of hemolysis: LDH $\geq \text{ULN}$ , haptoglobin $< \text{LLN}$ or schizocytes and impaired renal function (S-Creatinine $\geq \text{ULN}$ )	Age $\geq 12$ years No platelet decrease $>25\%$ during the 8-week observation period under $\geq 1$ PE/PI every 2 weeks but $\leq 3$ times per week for $\geq 8$ weeks Evidence of hemolysis: LDH $\geq \text{ULN}$ , haptoglobin $< \text{LLN}$ or schizocytes and impaired renal function (S-Creatinine $\geq \text{ULN}$ )	Age $\geq 1$ month to $<18$ years Body weight $\geq 5$ kg Platelet count $<150\text{G/L}$ Hemoglobin $< \text{LLN}$ LDH $\geq 1.5\times \text{ULN}$ S-Creatinine $\geq \text{ULN}$ No PE/PI for $>5$ weeks prior to enrollment	Age $\geq 18$ years Platelet count $<150\text{G/L}$ Hemoglobin $< \text{LLN}$ LDH $\geq 1.5\times \text{ULN}$ S-Creatinine $\geq \text{ULN}$ No specification for PE/PI prior to enrollment
Key exclusion criteria	No requirement for identified complement mutation or antibody	No requirement for identified complement mutation or antibody		
Baseline patients characteristics	ADAMTS13 activity $\leq 5\%$ ; STEC-HUS; prior eculizumab exposure			
- Median age, year (range)	28 (17–68)	28 (13–63)	Mean 6.5 (0.5–17.0)	Mean 40.3 (18–80)
- Identified complement mutation or anti-FH antibodies (%)	76	70	45	41
- History of kidney transplant (%)	41	40	9	22
- Median time from diagnosis of aHUS to screening, months (range)	9.7 (0.3–236)	48.3 (0.7–286)	0.6 (0.03–191)	0.79 (0.03–311)
- Median time from onset of current aHUS manifestation to screening, months (range)	0.75 (0.2–3.7)	8.6 (1.2–45)	0.2 (0.0–4.3)	0.5 (0.0–19.2)
- Median (range) or mean (SD) platelet count, G/L	Median 118 (62–161)	Median 218 (105–421)	Mean 87.5 (42.3)	Mean 119.1 (66.1)
- Mean eGFR, ml/min/1.73 m <sup>2</sup> (SD)	23(14.5)	31 (19)	32.7 (30.3)	17.3 (12.1)
- Dialysis within 8 weeks prior to first eculizumab dose or at baseline prior to first eculizumab dose (%)	35 (within 8 weeks)	10 (within 8 weeks)	55 (at baseline)	59 (at baseline)
- Median number of PE/PI prior to first eculizumab dose (range)	6 (0–7) during the week prior to first eculizumab dose	1.3 (1–3) during the week prior to first eculizumab dose	None in 55 % of patients during current manifestation of HUS prior to first eculizumab dose	None in 15 % of patients during current manifestation of HUS prior to first eculizumab dose

TMA: thrombotic microangiopathies; PE/PI: plasma exchange/plasma infusion; CKD: chronic kidney disease; LDH: lactate dehydrogenase; HUS: hemolytic uremic syndrome; ULN: upper limit of normal; LLN: lower limit of normal; eGFR: estimated glomerular filtration rate; STEC-HUS: *Escherichia coli*-hemolytic uremic syndrome

**Table 6** Efficacy of eculizumab in patients with atypical hemolytic uremic syndrome (HUS). Results of four prospective, open-label, single-arm, non-randomized, multinational trials at week 26 and aftercontinued treatment in the extension phase<sup>a</sup>. Primary efficacy end points for each trial are indicated in *bold*

	Trial 1 [13, 77]		Trial 2 [13, 77]		Trial 3 [79]	Trial 4 [80]	
Median treatment duration <sup>b</sup>	26 weeks	2 years	26 weeks	2 years	26 weeks	26 weeks	1 year
Mean change in platelet count from baseline (G/L)	<b>73</b>	<b>75</b>	/	/	164	135	116.9
Normalization of platelet count <sup>c</sup> (% patients)	<b>82</b>	<b>88</b>	90	90	95	98	100
Hematologic normalization <sup>c</sup> (% patients)	<b>76</b>	<b>88</b>	<b>90</b>	<b>90</b>	82	88	97
TMA event-free status <sup>c</sup> (% patients)	88	88	<b>85</b>	<b>95</b>	/	90	90
Complete TMA response with preserved renal function <sup>c</sup> (% patients)	/	/	/	/	/	<b>73</b>	<b>80.5</b>
Complete TMA response with improved renal function <sup>c</sup> (% patients)	65	76	25	55	<b>64</b>	56	56
Mean increase in estimated glomerular filtration rate (eGFR) from baseline, ml/min/1.73 m <sup>2</sup> (95 % CI)	32 (14–49)	35 (17–53)	6 (3–9)	7 (0.8–14)	64 (50–79)	29 (SD24)	30 (SD27)
Patients on dialysis at data cut-off (%)		12		10	9	15	12
Death	0	0	0	1 <sup>d</sup>	0	0	0

<sup>a</sup> All patients received recommended dosing regimen (Table 4) [75, 76]<sup>b</sup> Treatment duration indicates 26-week trial period and a median of 1 or 2 years total treatment duration including the extension phase, respectively. Data from extension phase are not available for trial 3.<sup>c</sup> Definition of efficacy end points:

- Hematologic normalization: Platelet count  $\geq 150$  G/L and lactate dehydrogenase (LDH)  $\leq$  under limits of normal (ULN) sustained for  $\geq 2$  consecutive measurements obtained  $\geq 4$  weeks apart
- Thrombotic microangiopathies (TMA) event-free status: absence for  $\geq 12$  consecutive weeks of a decrease of platelet count of  $>25$  %, no plasma exchange/plasma infusion (PE/PI) while receiving eculizumab and no initiation of new dialysis.
- Complete TMA response with preserved renal function: Platelet count normalization ( $\geq 150$  G/L) + LDH normalization ( $\leq$  ULN) +  $<25$  % increase of S-Creatinine from baseline, sustained for  $\geq 2$  consecutive measurements obtained  $\geq 4$  weeks apart
- Complete TMA response with improved renal function: Platelet count normalization ( $\geq 150$  G/L) + LDH normalization ( $\leq$  ULN) +  $\geq 25$  % decrease of S-Creatinine from baseline, sustained for  $\geq 2$  consecutive measurements obtained  $\geq 4$  weeks apart

<sup>d</sup> Death after 1.9 years of eculizumab treatment due to complications from gastrointestinal hemorrhage

TMA event-free status (see definition in Table 6) after a median treatment duration of 2 years. Mean (95 % CI) gain in eGFR was only 6 (3–9) ml/min/1.73 m<sup>2</sup> at 26 weeks, ( $p=0.0001$  versus baseline eGFR). However, eGFR gain was maintained after 2 years of continued treatment and correlated with shorter delay from onset of HUS episode to treatment initiation [13, 77]. In both trials, patients with or without identified complement abnormalities similarly met criteria for TMA event-free status and complete TMA response at the 1 and 2-year cut-offs [13, 77].

Two subsequent trials comprised 22 children and 41 adults, respectively. Both trials allowed early treatment initiation (brief screening period, no obligation for the patient to receive plasma therapy). Fifty-five percent of children received eculizumab as first-line therapy without prior PE/PI, compared to 15 % of adults. Complete TMA response with improved renal function (see definition in Table 6) was maintained after 26 weeks of treatment in 64 % of children [79], while 80 % of adult patients had complete TMA response with preserved renal function (see definition in Table 6) over 1 year treatment duration [80]. Renal function recovery was greater in the

pediatric compared to the adult cohort (64 ml/min/1.73 m<sup>2</sup> versus 29.3 ml/min/1.73 m<sup>2</sup> at week 26, respectively). Only 9 % (2/22) of children and 12 % (5/41) of adults required dialysis at 26 weeks and 1 year of continued eculizumab therapy, respectively [79, 80]. As observed in trial 1, mean gains in eGFR were less in transplanted than in non-transplanted adult patients ( $19.0 \pm 27.3$  ml/min/1.73 m<sup>2</sup> versus  $31.5 \pm 22.8$ ) [81].

The systematic review of the first two trials by the Advisory Group for National Specialized Services in the UK concluded that these studies indicated eculizumab was highly effective in patients with aHUS, despite study design limitations, including the possibility of a biased selection, the lack of control groups and the use of surrogate markers [82]. Trials 3 and 4 have the same limitations. The fact that only 40–45 % of patients in trials 3 and 4 had a complement abnormality, compared to 65 % in recently published cohorts [3] and 70–75 % in trials 1 and 2, raises the question of whether a few adult patients with secondary HUS or children with STEC-HUS (negative, inadequate, or non-documented STEC/Stx-assays) might have been included. Due to the limited number of patients in trial 3, no statistical comparisons could be performed

between results in children with no identified complement abnormality or with *MCP* mutation (both associated with more favorable prognoses in children in the pre-eculizumab era [3]) and those with less favorable mutations (in *CFH* or *C3*). Finally, the “best of all” recovery of renal function observed in children may have been due to early treatment initiation and/or a greater ability of pediatric kidneys to recover from TMA. However, results in trial 3 may have been biased by a few misclassified STEC-HUS cases, the high proportion of children without a complement abnormality or the lower proportion of children with post-transplant HUS compared to adults in trials 1 and 2. Despite these limitations, the four trials overall indicate that eculizumab is effective to stop the TMA process in patients with aHUS, allowing sustained remission of the disease and improved or preserved renal function in the majority of patients, including those resistant to PE/PI. Results also suggest that an early switch from PE/PI to eculizumab or the use of eculizumab as initial therapy may increase the chance of full recovery of renal function. Except for the occurrence of meningococcal meningitis in two of the 100 patients who entered these trials [80], treatment was well tolerated, with no treatment emergent adverse events.

#### Case reports of eculizumab to treat aHUS involving native kidneys

Among approximately 35 case reports of non-transplanted patients who received eculizumab to treat aHUS (cases with anti-CFH antibodies not included), 19 described children (median age 1.5 years (range, 11 days–11 years), 9 aged  $\leq 1$  year; 83 % (15/18 documented) with a complement mutation (*CFH*,  $n=10$ ; *CFI*,  $n=2$ ; *MCP*, *C3*, *CFB*,  $n=1$  each, no mutation identified,  $n=3$ ); 13 (66 %) requiring dialysis at baseline; 12 PE/PI-resistant and 2 PE/PI-dependent; first-line eculizumab in 5; median delay to eculizumab initiation, 19 (range,  $<1$ –225) days. After a median follow-up of 13 (range, 2.5–42) months of eculizumab therapy, all patients demonstrated sustained hematologic remission, only one out of 19 (5 %) received chronic dialysis and the median serum creatinine level was 43 (20–90)  $\mu\text{mol/l}$  in the remaining 18 children [12, 55, 83–92]. These results in children with severe forms of aHUS reinforce those of the prospective pediatric trial discussed above. In a recent series, the outcome of 19 eculizumab-treated adults was compared with that of paired historical controls treated only with PE/PI (63 % of cases). At 3-month follow-up, 17 % of the eculizumab group and 46 % of the “conventional therapy” group had reached ESRD ( $p=0.02$ ). The ESRD rate was 25 and 63 % respectively, at 1-year follow-up ( $p=0.04$ ). Patients treated with eculizumab within 6 days of onset tended to have lower final serum creatinine levels than those treated later [93]. Of note, no benefit from eculizumab treatment was demonstrated in seven patients with isolated DGKE mutation [9], while the benefit was

uncertain—clinical improvement but persistent proteinuria—in one patient with an associated *C3* variant [57]. The efficacy of eculizumab in DGKE mutation-associated HUS needs to be studied in a larger number of patients.

#### Case reports of eculizumab to treat or prevent post-transplant recurrence of aHUS

Most of the 17 patients treated for post-transplant recurrence outside of prospective trials were adults who carried high-risk mutations and/or had lost prior grafts due to recurrence [71, 73, 94–96]. Shorter interval between the onset of recurrence and treatment initiation was correlated with greater gain of graft function [71]. However, similar to transplanted patients included in prospective trials, many patients did not reach full return of graft function. This may be related in part to a variety of factors—predominantly ischemia-reperfusion injury—that induce endothelial damage in the graft and activate complement locally, particularly during the early post-transplant period and with more deleterious consequences in patients with preexisting complement dysregulation [97].

Prophylactic eculizumab treatment has been reported in 13 patients at high risk of post-transplant recurrence (previous grafts lost due to recurrence, 5/5; high-risk genetic abnormalities (*CFH*, *C3*, and *CFB* + *CFI* mutation), 13/13) [71, 98–101]. The schedule used for the prevention of humoral rejection in highly sensitized patients, consisted of a first dose a few hours before surgery and a second dose within the next 24 h, followed by standard recommended eculizumab dosing. Three patients received one PE before the pre-operative eculizumab dose(s). In three patients scheduled for living-donor transplantation and one on the urgent list for a deceased donor graft, eculizumab treatment was initiated 1 and 3 weeks before surgery, respectively [71, 98, 99]. Except for one patient with technically induced arterial graft thrombosis, who was ultimately successfully re-transplanted under prophylactic eculizumab therapy (communication of M. Hourmant, Nantes, France), all patients experienced a recurrence-free post-transplant course under continued eculizumab therapy, with serum creatinine level  $72 \pm 36$   $\mu\text{mol/l}$  at median follow-up of 17.5 (range, 2–39) months.

#### The risk of meningococcal infection under eculizumab

Immunity against *Neisseria meningitidis* depends on the lytic terminal complement complex C5b-9. The incidence of meningococcal infections in patients with congenital complete deficiency in terminal complement factors is 0.5 % per year, a relative risk of 5,000 compared to the normal population [102]. Prevention of meningococcal infection is therefore crucial in eculizumab-treated patients, relying on vaccination and antibiotic prophylaxis (Box 2) [103–106]. The tetravalent conjugated vaccines protect against serogroups A, C, W135 and Y, but not against serogroup B which predominates in



<b>Meningococcal vaccination</b>	<p><b>Meningococcal vaccination is mandatory</b>, before eculizumab initiation or as soon as possible if urgent eculizumab therapy is indicated</p> <p><b>Quadrivalent conjugate vaccines</b> (anti-A, C, Y, W) (Menactra™ (USA) (age &gt; 9 months), Menveo® (age ≥ 2 years) or Nimenrix® (age ≥ 1 year))</p> <p>Recent studies showed that Menveo® was well tolerated and highly immunogenic in healthy infants aged 2 to 12 months (103,104)<sup>a</sup></p> <p>+ <b>Anti-B vaccine</b> (Bexsero® (age ≥ 2 months), where available</p> <p><b>Efficacy of anti-meningococcal (vaccine) antibodies is uncertain in patients with complement deficiency, complement blockade or immunosuppressive therapy. We therefore recommend additional antibiotic prophylaxis, allowing prompt initiation of eculizumab.</b></p> <p>Patients with ESRD due to aHUS should be vaccinated prior to registration on the waiting list (105,106). Also consider vaccination of household close contacts (at least siblings and parents)<sup>b</sup>.</p>
<b>Antibioprophylaxis</b>	<p><b>Which antibiotics?</b></p> <p>Methylpenicillin (twice daily, full dose adapted to weight). Despite the reduced sensitivity of approximately 20% of meningococci towards penicillin, methylpenicillin retains its overall efficacy to prevent meningococcal infection.</p> <p>Macrolides in case of allergy to penicillin (however macrolides interfere with calcineurin inhibitors metabolism in transplanted patients)</p> <p>Avoid rifampicine or fluoroquinolone for long term prophylaxis, to limit the risk of inducing bacterial resistance (except in case of contact with a patient with invasive meningococcal infection)</p> <p>Other antibiotics may be recommended by local experts</p> <p><b>Which duration?</b></p> <p>Obligatory during 2 weeks after vaccination in patients receiving eculizumab</p> <p>Obligatory in some countries (France, UK) as long as the patient receives eculizumab (+ 60 days after eculizumab discontinuation)</p> <p>Discrepant current practice in other countries</p> <p>Continuous antibioprophylaxis is recommended by the majority of authors of this review</p>
<b>Education information card</b>	<p>Education on signs of meningococcal infection to ensure early recognition and treatment</p> <p>Consider prescription of ceftriaxone for immediate access at home in remote areas</p> <p>Travel/holidays should be carefully prepared (information on meningococcal epidemiology in the visited country, prior written contact with local teams, information to the patient of where to go, which doctor/department/phone numbers...)</p> <p><b>Information card</b> to be carried by the patient or his/her care giver, to be shown to medical staff in case of symptoms suggesting infection</p>

**Box 2** Prevention of meningococcal infection in patients treated with eculizumab. a. No official recommendation has been given for its use in children younger than 2 years of age b. Carriage rate of meningococci is

the highest in adolescents and young adults (up to 30 % between age 16 and 24)

European countries, North America, Australia and New Zealand. While a vaccine against *N. meningitis* B is now available in some countries (Bexsero), data on its clinical efficacy and duration of protection under complement blockade are still pending. Despite vaccination, the incidence of invasive meningococcal infection has been approximately 0.5 per 100 patient-years in patients with paroxysmal nocturnal hemoglobinuria (PNH) treated with eculizumab [107]. Two of the 100 aHUS patients treated within protocols [80] and one among approximately 80 case reports [106] had invasive meningococcal infection despite being vaccinated. However the latter patient had been vaccinated using the polysaccharide vaccine. Neither vaccines nor antibioprophylaxis guarantee full protection, hence the importance of patient/family education on signs of meningococcal infection and of an information card to be carried by patients or their care-giver (Box 2).

### Clinical practice recommendations for patients with atypical HUS in 2014

What should be first-line treatment and when should it be started in a child with a clinical diagnosis of aHUS?

For children with a clinical diagnosis of aHUS, we propose eculizumab as first-line treatment, to avoid PE and the complications of central venous double line catheters. In such

cases, confirmation of a complement mutation is not required prior to treatment initiation. Based on the reviewed literature, undue treatment delay may affect ultimate renal recovery and increase the risk of early progression to ESRD [13, 77, 93]. When possible, eculizumab treatment should be initiated within 24–48 h of onset or admission. If eculizumab is not (or not immediately) available, PE (or PI if PE is not possible) should be started as recommended in the 2009 guideline [10].

While the indication of complement blockade treatment is not limited to aHUS patients with a confirmed complement mutation as this treatment is also effective in patients without complement mutation, genetic screening is required for the longer-term management of patients. Anti-CFH antibody testing is the only complement investigation urgently needed during the acute phase, as a positive result raises additional treatment options.

Treatment of anti-CFH antibody-associated HUS: an area for future studies

The first large series of patients with anti-CFH antibody-associated HUS treated mostly with PE without immunosuppressants reported a poor outcome including death in 9 %, relapses in 58 %, CKD in 39 % and ESRD in 27 % after a mean follow-up of 39 (range, 1–168) months (Table 3) [50]. However, in a recent cohort of children with this form of aHUS who were treated early with PE, immunosuppressants and corticosteroids,



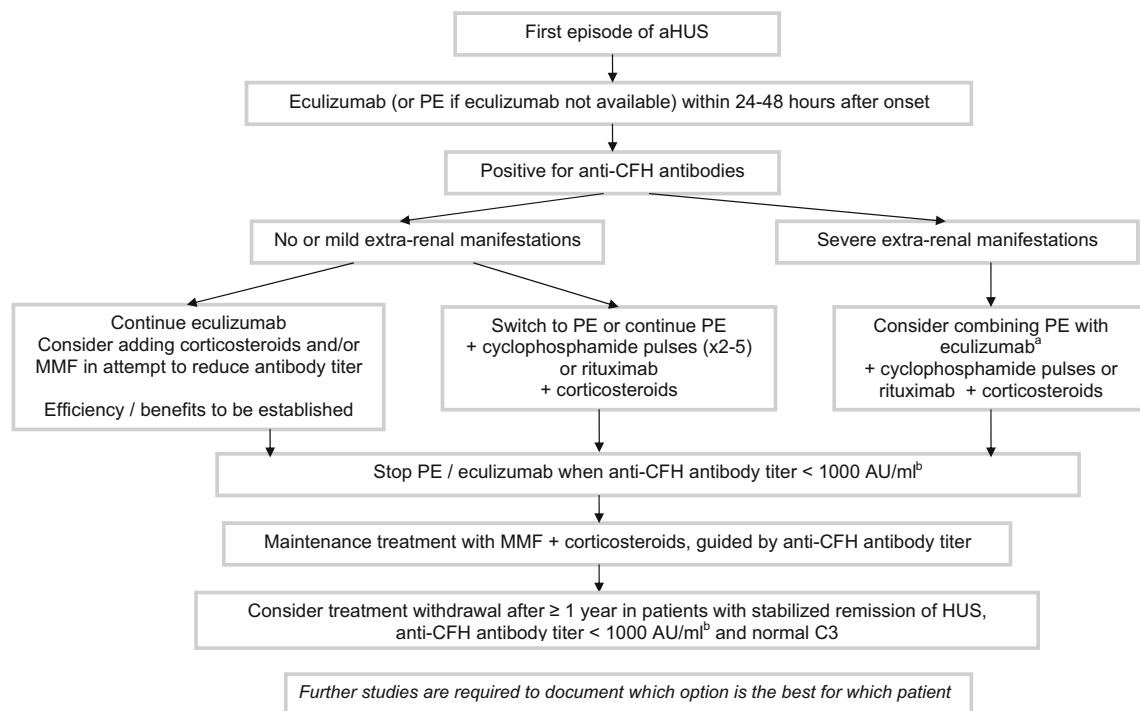
outcome was much more favorable, similar to that of MCP-HUS [3]. Another report of 138 Indian children with anti-CFH antibody-associated HUS confirmed that combined PE and immunosuppression (oral prednisolone with cyclophosphamide or rituximab in 77 % of patients) reduced antibody titer to  $\leq 1,000$  AU at a median of 32 (interquartile range, 11–84) days [52]. This was associated with hematological remission and significant reduction of adverse outcomes (defined as eGFR  $<30$  ml/min/1.73 m<sup>2</sup> or death) by the combined therapy, from 71 to 33 % after a mean follow-up 14.5 (range, 3–95) months. Anti-CFH antibody titer guided maintenance treatment with corticosteroids and mycophenolate mofetil (MMF) or azathioprine. Using a threshold of  $> 2000$  AU/ml [50, 52] significantly increased the probability of a relapse-free survival, from 46 to 87 % at last follow-up [52]. Four patients have been reported who went into remission after a short cyclophosphamide pulse therapy (0.5 g/1.73 m<sup>2</sup>  $\times$  2 in three patients, 1 g/1.73 m<sup>2</sup>  $\times$  5 in one patient resistant to PE + rituximab) combined with PE and prednisone, and had full renal recovery up to 6 years, 4 years, and 4 months without any maintenance therapy [108]. Although experience is limited, eculizumab appears to be effective in anti-CFH antibody-HUS [93, 109–111]. However, eculizumab is not expected to inhibit anti-CFH antibody production and a spontaneous decline in anti-CFH antibodies is rare [50]. Lastly, eculizumab should be considered in patients with acute, severe injury of vital organs, such as brain and heart due to this form of HUS [110]. Figure 3 proposes a practical treatment algorithm. However, additional studies are

required to establish the respective place of eculizumab, PE, cyclophosphamide pulses, rituximab and MMF for optimal treatment of anti-CFH antibody-associated HUS.

What should be first-line treatment and when should it be started when presentation is incomplete or uncommon or the diagnosis uncertain?

Some children with aHUS do not present with the full triad of HUS, as they may not be thrombocytopenic (15 %) or anemic (6 %) or they may have preserved renal function initially (17 %) [3, 112]. Rarely, patients may present with heavy proteinuria and anemia without thrombocytopenia, or severe hypertension with or without hematological abnormalities or renal impairment. Kidney biopsy is useful in such cases to confirm TMA lesions (thrombi, capillary walls thickening with double contours) [6, 7, 12]. Occasionally, the clinical differentiation between STEC-HUS, TTP, cblC defect-HUS and aHUS may be difficult, and initial treatment will rely on the clinician's judgment. Rapid results of confirmatory assays should prevent undue delay of the best-treatment decision.

Up to 30 % of typical/post-diarrheal HUS cases may not be confirmed as STEC-positive by stool culture, Stx detection or serological (anti-lipopolysaccharide antibodies antibody) assays [26–28]. In such cases, the clinical diagnosis of presumed STEC-HUS entails supportive treatment only. The role of eculizumab in STEC-HUS is beyond the scope of this review and needs assessing in a clinical trial setting.



**Fig. 3** Proposed treatment algorithm for anti-CFH antibody-associated HUS. **a** As PE clears eculizumab from the circulation, eculizumab has to be reinfused at the end of each PE. **b** The titer required when using a non-

standardized assay is unknown. aHUS: atypical hemolytic uremic syndrome; CFH: complement factor H; MMF: mycophenolate mofetil; PE: plasma exchange

Conversely, treatment of antibody-associated TTP is based on PE + corticosteroids  $\pm$  rituximab, and treatment of congenital TTP is PI 10 ml/kg that suffices to induce remission. The demonstration of complement activation in TTP [113–117] does not suffice to propose eculizumab as an alternative treatment [5–8]. The single adult patient with TTP resistant to PE and all current medications who went into remission under eculizumab [118] was subsequently found to have anti-CFH antibodies and no severe ADAMTS13 deficiency despite having anti-ADAMTS13 antibodies [119]. This association, also reported in one child [11], suggests that screening for anti-CFH antibody might be indicated in children with antibody-associated TTP or whenever TTP does not respond to standard treatment.

If first-line treatment has been PE or PI in a patient with aHUS, should the patient be offered eculizumab?

In children who have commenced PE or PI as first-line therapy during the acute phase, we propose a switch to eculizumab when the diagnosis of aHUS is established. Exceptions to this recommendation would be patients who have anti-CFH antibodies (Fig. 3). We also propose that patients who fail to respond to plasma therapy be switched to eculizumab: the patient who, after approximately five daily PE/PI has no constant upward trend of platelet count (particularly if the platelet count remains  $<150 \times 10^9/l$ ), or is without a constant downward trend of LDH level (particularly if LDH remains  $>$  upper limit of normal (ULN)), or has no significant decrease (at a minimum  $\geq 25\%$  decrease) in serum creatinine should be switched to eculizumab [7, 12]. Our recommendation is based on the data which suggests that this offers the patient the best chance of optimal recovery of renal function. The answer is more difficult for patients on long-term plasma therapy. Pragmatically, there is no reason to change therapy in patients who have full remission and normal renal function (eGFR  $>90$  ml/min/1.73 m<sup>2</sup>, no proteinuria, no hematuria, no hypertension requiring multi-drug therapy) under a schedule of PE/PI compatible with their daily activity, without catheter-bound complications or plasma intolerance. Conversely, the switch to eculizumab should be considered if any sign of subclinical hemolytic activity (LDH  $>$  ULN, haptoglobin  $<$  lower limit of normal (LLN)) or renal TMA (isolated proteinuria or slowly increasing serum creatinine level with active TMA confirmed at renal biopsy) appears [120]. This also applies for patients with normalized hematologic markers of TMA but residual CKD under long-term PE/PI therapy [13, 77]. Extra-renal manifestations of TMA (neurologic, cardiac, vascular, among others) are another reason to switch the patient from PE/PI to eculizumab.

Is eculizumab effective for the treatment of extra-renal manifestations of aHUS?

Experience in this domain is limited. However, eculizumab was impressively effective in two children with life-threatening aHUS and acute distal ischemia (digital gangrene) [55] and skin necrosis with intestinal perforation [121], and two adults with ulcerative skin lesions [122]. That eculizumab may be efficacious to rescue central nervous system involvement is suggested by nine case reports, including four in children [87, 90, 110, 123–127]. Eculizumab also appeared life-saving in four children with myocardial involvement [83, 90, 92, 110]. The reports of four children who developed cerebral ischemic events due to stenosis of cerebral arteries after several years on dialysis have suggested that local complement activation added to the vascular consequences of long-term dialysis may lead to such macrovascular complications [101, 128–130]. Two of these patients stopped having ischemic events under eculizumab therapy, with non-progression of arterial stenoses documented in one [101, 129].

In dialyzed patients, when is it too late to start or useless to maintain eculizumab treatment in order to rescue renal function?

The answer to this question is not well supported by evidence. We are aware of two patients who started eculizumab after 90 and 225 days on dialysis and did not recover renal function [55, 131], but also of two patients who recovered normal [132] or nearly normal [133] serum creatinine levels despite eculizumab initiation after 4 and 3.5 months on dialysis, respectively. Therefore eculizumab treatment is reasonable to consider for patients requiring dialysis for 3–4 months or even more and should be maintained for at least 3–6 months before concluding there has been no benefit. A kidney biopsy may be useful for the decision of eculizumab initiation or maintenance in patients requiring dialysis for approximately 3 months, according to the presence of active TMA lesions suggesting therapy initiation, or diffuse irreversible sclerotic/fibrotic ischemic lesions, for which eculizumab would not be expected to be helpful.

In patients on long-term dialysis, is it justified to maintain eculizumab treatment to prevent potential cerebral, cardiac, or macrovascular complications of aHUS?

In our opinion, there is insufficient evidence to answer this question. Studies are required to document the frequency of large artery involvement and cerebro/cardio-vascular complications in aHUS patients compared to patients on chronic dialysis for other reasons [134]. Alternatively, any new or ongoing vascular manifestation justifies complement blockade therapy when no other cause than the TMA process is identified.

Is it necessary to check that complement blockade is complete in patients under eculizumab? Which biological assays are available for that?

Our recommendations here are based on data from the prospective studies reviewed earlier. Complement blockade is obtained within 1 h after the first dose [13]. Most patients under recommended treatment schedules (doses and intervals according to weight in children) (Table 4) have full complement blockade between doses. Assessment of complement blockade may be justified at day 7, just before the second dose. If complement blockade is not obtained, identification of the cause of incomplete blockade is needed. It may be due to insufficient dose, especially in children slightly below a weight requiring a higher dose. Another rare reason is leakage of the drug into the urine in the case of massive proteinuria with nephrotic syndrome, as observed in rare cases of aHUS. Lastly, non-blockade of complement despite appropriate dose of eculizumab may have a genetic explanation, such as the recently reported C5 variant which prevents the binding of eculizumab to C5. This C5 polymorphism (also found in the normal Japanese population) has been identified in Japanese and Asian-origin patients with PNH who were resistant to eculizumab [135]. This variant might have to be considered in aHUS patients of Japanese or Asian origin with complement non-blockade under eculizumab and/or a poor response to eculizumab. For the long term, checking whether complement blockade is maintained is unnecessary except if there are clinical concerns, particularly in situations known to trigger complement activation, such as infection, immunization, elective surgery, kidney transplantation or pregnancy and postpartum period. Checking complement blockade is also necessary in situations of apparent resistance to eculizumab, including full-blown relapses, but also when abnormalities occur in the platelet counts, LDH and/or haptoglobin levels when previously normalized, or if a progressive increase in proteinuria or serum creatinine is observed, especially if renal biopsy shows signs of ongoing TMA. Checking the resolution of complement blockade after eculizumab withdrawal may also be useful to decide when antibioprophylaxis can be stopped.

The current available markers of complement blockade used to monitor eculizumab treatment are a CH50 or other hemolytic-based assays or the Wieslab Complement System [136]. A CH50 is the most available. Eculizumab treatment is expected to suppress CH50 activity, i.e.,  $\text{CH50} < 10\%$  of normal value. A relevant limitation is that CH50 cannot be used in patients with complete CFH deficiency (homozygous CFH mutation) in whom CH50 levels are permanently undetectable. Based on the site of action of eculizumab, a low C3 level such as seen in some mutations is not expected to normalize under eculizumab. Soluble C5b-9 plasma levels remain detectable or increased in aHUS patients treated with eculizumab [67, 88] and therefore cannot be recommended

to monitor the efficacy of eculizumab in clinical practice. Published data on the correlation between eculizumab trough levels and complement blockade, although limited, suggest that eculizumab trough levels at or over 100  $\mu\text{g/ml}$  markedly reduce CH50 activity, while levels below 50  $\mu\text{g/ml}$  do not [107]. Notwithstanding their limited availability, eculizumab levels currently appear to provide an optimal way to monitor eculizumab treatment, when indicated. However, data on the relationship between drug levels and complement activity in aHUS patients are still required. Note that the majority of patients treated within the prospective trials according to the protocol schedule had suppression of CH50 activity and eculizumab trough levels  $\geq 150\ \mu\text{g/ml}$  [13].

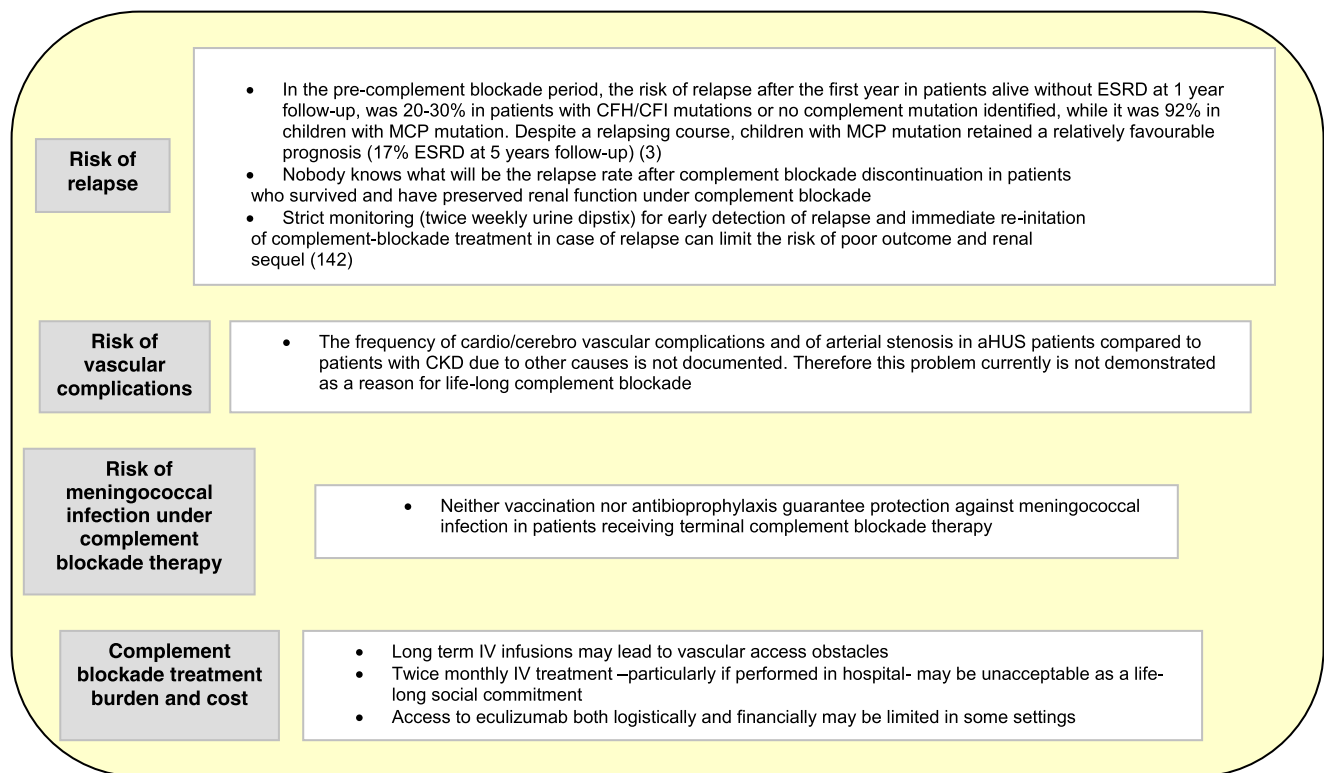
In a patient in remission of aHUS under eculizumab, can the interval between doses be increased?

The current treatment paradigm is that permanent C5 blockade with eculizumab should be maintained in aHUS patients to prevent relapses and reactivation of the renal TMA process. Therefore, increasing the interval between doses (or decreasing dose) should be considered only in patients who maintain CH50 activity  $< 10\%$  despite longer intervals or lower doses, as recently reported [136]. The concomitant evaluation of trough levels of the drug will be very useful to guide modifications of treatment schedule. In common clinical practice, lengthening the time between doses or decreasing the dose without confirming complement blockade will likely precipitate periods of inadequate complement blockade. In our opinion, it is more rational either to treat or stop treating, rather than provoking a sinusoidal coverage regimen. Notice that failure to maintain C5 blockade may not immediately induce a risk of relapse or reactivation of the renal TMA process.

What duration of eculizumab treatment for aHUS in patients with their native kidneys, but not on maintenance dialysis?

The 2014 issues of the Summary of Product Characteristics of the European Commission [75] and of the Full Prescribing Information of the Food and Drug Administration [76] do not take position on treatment duration. They inform on the risk of relapse after discontinuation and how to cope with it.

Reasons to reconsider the hitherto recommended “life long treatment” for all patients have emerged progressively and are summarized in Box 3. Experience with eculizumab withdrawal today is limited. No data is published about the patients treated within the prospective trials who stopped treatment. In the early eculizumab era, three patients who received a single dose all had relapse of HUS after 1 to 2 months [83, 137, 138]. A single dose regimen should no longer be considered. As indicated in Table 7 [84, 87, 93, 125–127, 139–142], three of four patients with a CFH mutation had relapse of HUS after eculizumab withdrawal. Early eculizumab re-initiation



**Box 3** Reasons to reconsider the recommendation of life-long complement blockade treatment for all patients after a first episode of atypical HUS involving native kidneys. aHUS: atypical hemolytic

uremic syndrome; CFH: complement factor H; CFI: complement factor I; CKD: chronic kidney disease; ESRD: end-stage renal disease MCP: membrane cofactor protein (CD46)

allowed remission and rescue of renal function in all patients, but one of them required 3 weeks dialysis despite being re-treated within 3 days of relapse onset [139]. Conversely, the risk of relapse after eculizumab withdrawal seems to be lower in patients with isolated *CFI* or *MCP* mutation or no mutation identified. Last, as expected, the risk of relapse in anti-CFH antibody-associated HUS depends on the antibody titer. In summary, although limited, current published experience suggests caution when considering discontinuation of treatment in patients with *CFH* mutation. On the other hand, withdrawal after a few months of full recovery appears reasonable in children with an isolated *MCP* mutation, possibly also in those with isolated *CFI* mutations, no mutation identified or a rare variant of unknown functional consequences. The majority of the authors of this review agree that children with *MCP* mutations should be treated with eculizumab during acute episodes, because an untreated episode can result in ESRD (17 % of children after a median follow-up of 5 years) [3] (Table 3, row 4). Preventing ESRD in one out of five children is not trivial. Possible exceptions to this recommendation could be children with mild renal impairment during acute episodes, long intervals (>1 year) between episodes and/or isolated heterozygous *MCP* mutation [59].

In practice, prospective studies under strict monitoring, involving patients with and without mutations, are required to

establish whether treatment withdrawal is feasible and safe, in which patients and when. In our opinion, withdrawal should not be considered in patients who had life-threatening initial presentation or relapses (e.g., severe neurologic manifestations, myocardial failure) or in children who did not fully recover normal renal function. Except for children with *MCP* mutations, withdrawal should probably be postponed until the child is more than 3 to 5 years old, the age when seasonal infections, which may trigger relapse, become less frequent.

### Kidney transplantation for patients with atypical HUS in 2014

Choice of the donor and practical issues for the prevention of atypical HUS recurrence after kidney transplantation

As indicated above, the risk of post-transplant recurrence is mostly determined by genetics and, in patients with anti-CFH antibodies, the anti-CFH antibody titer. Complete genetic screening and anti-CFH antibody assay are required before listing the patient for kidney transplantation. However, a few aHUS patients at high risk of post-transplant recurrence (e.g., hybrid CFH and/or prior graft lost after recurrence) did well

**Table 7** Outcome according to complement anomaly after eculizumab withdrawal in 20 patients with atypical hemolytic uremic syndrome (HUS) involving their native kidneys

Author (Reference)	Age (years)	Complement anomaly	Eculizumab treatment duration until withdrawal (months)	Relapse of HUS after eculizumab withdrawal	Delay between eculizumab withdrawal and relapse (months)	Change in S-Creatinine at relapse ( $\mu\text{mol/l}$ )	S-Creatinine at last follow-up ( $\mu\text{mol/l}$ )	Follow-up after eculizumab withdrawal or re-initiation <sup>c</sup> (months)
Carr et al. [139]	20 (PP)	CFH mutation	9 months	Yes	6	Normal $\rightarrow$ 451 (3 weeks dialysis)	ND (free of dialysis)	ND
Delmas et al. [140] <sup>a</sup> and Fakhouri et al. (Patient 1) [93]	26 (PP)	CFH + CFI mutation	18 months	No	NA	NA	70	18
Ardissino et al. [142] Patient 1	4.3	CFH mutation	5.5 months	Yes	1.5	71 $\rightarrow$ 248	71	25
Ardissino et al. [142] Patient 2	37.7	CFH mutation	14 months	Yes	0.9	124 $\rightarrow$ 203	115	10
Cayci et al. [84] <sup>b</sup>	11	CFI mutation	2 weeks	No	NA	NA	48	11
Ardissino et al. [142] Patient 3	52.7	CFI mutation	1.5 month	No	NA	NA	88.5	22
Ardissino et al. [142] Patient 4	34.8	CFI mutation	11.5 months	No	NA	NA	221	10
Ardissino et al. [142] Patient 5	2.6	CFI mutation	5.5 months	No	NA	NA	35	15.5
Gulleroglu et al. [87] Patient 2	6	MCP mutation	5 weeks	No	NA	NA	Normal	9
Fakhouri et al. [93] Patient 2	22	MCP mutation	8 weeks	No	NA	NA	84	11
Ardissino et al. [142] Patient 8	5.4	MCP mutation	0.5 month	No	NA	NA	44	13.5
Fakhouri et al. [93] Patient 4	49	Anti-CFH Ab <sup>d</sup>	8 weeks	No	NA	NA	88.5	10
Ardissino et al. [142] Patient 7	19.1	Anti-CFH Ab <sup>e</sup>	5.5 months	No	NA	NA	106	14.5
Ardissino et al. [142] Patient 9	13.3	Anti-CFH Ab <sup>f</sup>	2.5 months	No	NA	NA	53	8.5
Ardissino et al. [142] Patient 10	10.9	Anti-CFH Ab <sup>g</sup>	0.4 months	Yes	1	62 $\rightarrow$ 301	53	5
Pu et al. [126]	85	None identified	3 months	No	NA	NA	Normal	12
Beye et al. [125]	64	ND	13 weeks	No	NA	NA	60	6
Canigral et al. [141]	32 (PP)	None identified	6 months	No	NA	NA	88.5	12
Chaudhary et al. [127]	20	None identified	9 months	No <sup>h</sup>	NA	NA	70.8	$\approx$ 9
Ardissino et al. [142] Patient 6	1.3	None identified	13.5 months	No	NA	NA	26	6.5

Ab: antibodies; CFH: complement factor H; CFI: complement factor I; MCP: membrane cofactor protein (CD46); NA: not applicable; ND: not documented;

PP: post-partum

<sup>a</sup> Communication of Y. Delmas, Bordeaux, France

<sup>b</sup> Communication of FS Altugan-Cayci, Ankara, Turkey

<sup>c</sup> Eculizumab treatment was re-initiated in the four patients who relapsed after eculizumab withdrawal

<sup>d</sup> Anti-CFH antibody negativated under rituximab + steroids

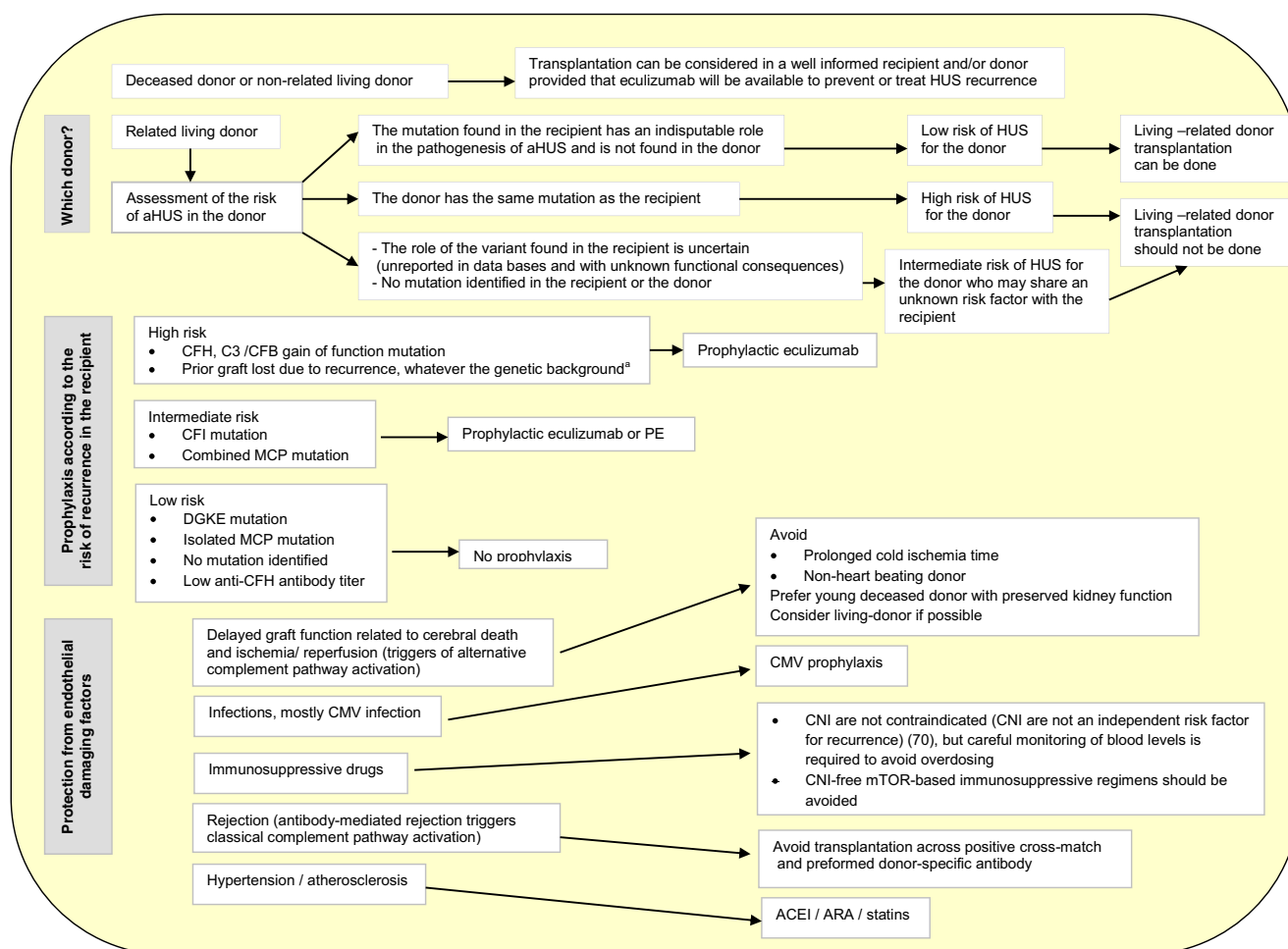
<sup>e</sup> Prophylactic eculizumab to prevent post-transplant recurrence. Anti-CFH antibody titer (27 IU); Upper limit of normal in healthy controls: 5.2 IU (Communication of G. Ardissino, Milan, Italy)

<sup>f</sup> Anti-CFH antibody titer: 100 IU (see<sup>e</sup> for normal titer)

<sup>g</sup> Anti-CFH antibody titer: 230 IU (see<sup>e</sup> for normal titer)

<sup>h</sup> Hypertension + heavy proteinuria (pre-eclampsia) at 34 weeks pregnancy, without signs of HUS; recovery after delivery: residual hypertension





**Box 4** Practical issues for the management of kidney transplantation in patients with atypical HUS (aHUS). a Including patients with no mutation identified who experienced recurrence on a prior graft. ACEI: Angiotensin-converting enzyme inhibitors; ARA: Angiotensin receptor

antagonists; CFB: complement factor B; CFH: complement factor H; CFI: complement factor I; CNI: calcineurin inhibitors; DGKE: diacylglycerol kinase  $\epsilon$ ; MCP: membrane cofactor protein (CD46); PE: plasma exchange

without any prophylactic therapy, showing that prediction and decisions are difficult [143, 144]. Genetic screening of the recipient and the donor is also a prerequisite when transplantation with a living-related donor is considered. Lastly, measures to protect endothelium from damaging factors that may trigger complement activation have to be taken into account (Box 4).

In patients at high risk of post-transplant recurrence, should prophylactic eculizumab treatment be applied or should the physician wait for recurrence to start eculizumab?

As indicated above, patients with post-transplant HUS treated with eculizumab often do not reach full return of graft function. We consider that the aim in 2014 should be to offer the best possible graft function to aHUS patients and therefore we favor prophylactic eculizumab in patients at high risk of recurrence. However, this position raises the question of

treatment withdrawal when the period of maximum risk of recurrence, i.e., the first year [70], is over. Our position on this point is as follows: rigorously conducted studies of eculizumab withdrawal in patients treated for aHUS involving native kidneys is a more appropriate starting point. If this shows a high percentage of early relapses in patients with high-risk mutations, then stopping eculizumab in transplanted patients with the same type of mutations will be contraindicated. If not, controlled withdrawal studies in transplanted patients treated prophylactically will be justified. As of today, we propose that withdrawal should not be considered in patients treated for post-transplant recurrence of aHUS.

What is the place of combined liver–kidney transplantation in aHUS in 2014?

Liver transplantation (LT) or combined liver–kidney transplantation (CLKT) in patients with severe aHUS and

mutations of complement factors synthesized in the liver (CFH, CFB and C3) is the only option to cure aHUS. J. Saland recently summarized information he collected from 20 patients with *CFH* ( $n=18$ ), *CFB* ( $n=1$ ) or *C3* ( $n=1$ ) mutations, who received combined CLKT ( $n=19$ ) or LT ( $n=1$ ) with a preparative regimen of pre-operative PE (+peri-operative PI) ( $n=18$ ) or eculizumab ( $n=2$ ) with ( $n=1$ ) or without ( $n=1$ ) one PE session just before eculizumab [145]. To date, 16 patients (80 %) were cured from HUS with both grafts functioning, three died in the post-operative period (3/19 CLKT, 16 %) and one had a non-functioning kidney graft due to per-operative hemodynamic instability. To our knowledge, the three deaths were related to vascular complications in patients who had been on dialysis for years. We were recently informed of an additional patient with a *CFH* mutation who died from fungal infection 3 months post-CLKT prepared with PE + eculizumab (personal communication from G. Lipkin, Birmingham, UK). Lastly, a child with a *CFH* mutation has recently been reported who was cured from aHUS after preemptive living-non-related donor LT under PE/PI coverage [146]. Although most groups would rather take the option of kidney transplantation under eculizumab, CLKT should not be discarded and all options should be discussed with patients and families. The decision can only be taken on a case-by-case basis, determined by risks/benefits assessment and, for some patients, their country's ability to cover the cost of long-term eculizumab treatment after isolated kidney transplantation [12, 97]. Preemptive LT may be an option for patients with preserved eGFR despite a severe/relapsing course and with a *CFH*, *CFB*, or *C3* mutation, complications or no benefit from PE/PI and no access to eculizumab treatment.

## Conclusions

Our understanding of the role of the complement AP in the pathogenesis of a large fraction of patients with aHUS and the availability of eculizumab, an inhibitor of the terminal complement pathway, has dramatically changed our approach to aHUS. In this review, we have addressed the questions faced by clinicians world-wide, and tried to give evidence-based answers where available, and use the published anecdotal literature where such data were missing. Our discussion will raise as many questions as it answers, and ongoing clinical experience and trials will help answer some, while new trials will need to be designed to answer others.

The geographical disparity in treatment availability due to the cost of the drug is today a major problem. We anticipate that the cost of eculizumab may fall with other indications and as new agents under development emerge. We expect carefully designed studies and data from registries to establish safe withdrawal of treatment in order to reduce treatment burden to the patient and the overall cost to health care systems.

**Acknowledgments** The authors wish to thank DR MK Taha, Institute Pasteur, Invasive Bacterial Infections Unit and National Reference Centre for Meningococci, Paris, France, for his helpful insights on the debate of meningococcal infection prophylaxis

**Authors contribution** C. Loirat, F. Fakhouri and V. Fremeaux-Bacchi participated in the concept, design and writing of the article. C. Loirat, V. Fremeaux-Bacchi, G. Ariceta, S. Johnson, AL. Lapeyraqe, and C. Nester participated to a meeting in Paris on February 26, 2014, to define the domains requiring discussion and consensus.

Four critical revisions of the article and consensus approval of the final version was given by the authors indicated above and by M. Bitzan, R. Coppo, F. Emma, D. Karpman, D. Landau, C.B. Langman, C. Licht, M. Riedl, N. van de Kar and M. Vivarelli. N. Besbas, A. Bjerre, C. Pecoraro and J. van de Walle gave approval of the revisions and final version. All authors except F. Fakhouri and V. Fremeaux-Bacchi are members of HUS International.

**Declaration of interests** The following authors declare interests. G. Ariceta, F. Fakhouri, V. Fremeaux-Bacchi, S. Johnson, D. Landau, AL. Lapeyraqe, C. Licht, C. Loirat and N. van de Kar have served on Advisory Boards and/or teaching courses for Alexion Pharmaceuticals. C. Licht received research grants from Alexion Pharmaceuticals. D. Karpman, C. Licht and C. Loirat were the national coordinators of the multi-center Eculizumab trials in aHUS in Sweden, Canada and France, respectively. G. Ariceta, F. Fakhouri, V. Fremeaux-Bacchi, S. Johnson, C. Licht and J. van de Walle are members of the Scientific Advisory Board of the International aHUS Registry of Alexion Pharmaceuticals. M. Bitzan and C. Loirat were scientific advisers for Thallion Pharmaceuticals. C. Licht served on Advisory Board of Achillon Pharmaceuticals.

## References

1. Noris M, Caprioli J, Bresin E, Mossali C, Pianetti G, Gamba S, Daina E, Fenili C, Castelletti F, Sorosina A, Piras R, Donadelli R, Maranta R, van der Meer I, Conway EM, Zipfel PF, Goodship TH, Remuzzi G (2010) Relative role of genetic complement abnormalities in sporadic and familial aHUS and their impact on clinical phenotype. *Clin J Am Soc Nephrol* 5:1844–1859
2. Maga TK, Nishimura CJ, Weaver AE, Frees KL, Smith RJ (2010) Mutations in alternative pathway complement proteins in American patients with atypical hemolytic uremic syndrome. *Hum Mutat* 31: E1445–E1460
3. Fremeaux-Bacchi V, Fakhouri F, Garnier A, Bienaimé F, Dragon-Durey MA, Ngo S, Moulin B, Servais A, Provot F, Rostaing L, Burtey S, Niaudet P, Deschênes G, Lebranchu Y, Zuber J, Loirat C (2013) Genetics and outcome of atypical hemolytic uremic syndrome: a nationwide French series comparing children and adults. *Clin J Am Soc Nephrol* 8:554–562
4. Kavanagh D, Goodship TH, Richards A (2013) Atypical hemolytic uremic syndrome. *Semin Nephrol* 33:508–530
5. Nester CM, Thomas CP (2012) Atypical hemolytic uremic syndrome: what is it, how is it diagnosed, and how is it treated? *Hematology* 2012:617–625
6. Campistol JM, Arias M, Ariceta G, Blasco M, Espinosa M, Grinyó JM, Praga M, Torra R, Vilalta R, Rodríguez de Córdoba S (2013) An update for atypical haemolytic uraemic syndrome: diagnosis and treatment. A consensus document. *Nefrologia* 33:27–45
7. Cataland SR, Wu HM (2014) How I treat: the clinical differentiation and initial treatment of adult patients with atypical hemolytic uremic syndrome. *Blood* 123:2478–2484

8. Scully M, Goodship T (2014) How I treat thrombotic thrombocytopenic purpura and atypical haemolytic uraemic syndrome. *Br J Haematol* 164:759–766
9. Lemaire M, Frémeaux-Bacchi V, Schaefer F, Choi M, Tang WH, Le Quintrec M, Fakhouri F, Taque S, Nobili F, Martinez F, Ji W, Overton JD, Mane SM, Nürnberg G, Altmüller J, Thiele H, Morin D, Deschenes G, Baudouin V, Llanas B, Collard L, Majid MA, Simkova E, Nürnberg P, Rioux-Leclerc N, Moeckel GW, Gubler MC, Hwa J, Loirat C, Lifton RP (2013) Recessive mutations in DGKE cause atypical hemolytic-uremic syndrome. *Nat Genet* 45:531–536
10. Ariceta G, Besbas N, Johnson S, Karpman D, Landau D, Licht C, Loirat C, Pecoraro C, Taylor CM, Van de Kar N, Vandewalle J, Zimmerhackl LB, European Paediatric Study Group for HUS (2009) Guideline for the investigation and initial therapy of diarrhea-negative hemolytic uremic syndrome. *Pediatr Nephrol* 24:687–696
11. Johnson S, Stojanovic J, Ariceta G, Bitzan M, Besbas N, Karpman D, Frieling M, Landau D, Langman C, Licht C, Pecoraro C, Riedl M, Siomou E, Van de Kar N, Walle JV, Loirat C, Taylor CM (2014) An audit analysis of a guideline for the investigation and initial therapy of diarrhea negative (atypical) hemolytic uremic syndrome. *Pediatr Nephrol* 29:1967–1978
12. Zuber J, Fakhouri F, Roumenina LT, Loirat C, Frémeaux-Bacchi V, French Study Group for aHUS/C3G (2012) Use of eculizumab for atypical haemolytic uraemic syndrome and C3 glomerulopathies. *Nat Rev Nephrol* 8:643–657
13. Legendre CM, Licht C, Muus P, Greenbaum LA, Babu S, Bedrosian C, Bingham C, Cohen DJ, Delmas Y, Douglas K, Eitner F, Feldkamp T, Fouque D, Furman RR, Gaber O, Herthelius M, Hourmant M, Karpman D, Lebranchu Y, Mariat C, Menne J, Moulin B, Nürnberger J, Ogawa M, Remuzzi G, Richard T, Sberro-Soussan R, Severino B, Sheerin NS, Trivelli A, Zimmerhackl LB, Goodship T, Loirat C (2013) Terminal complement inhibitor eculizumab in atypical hemolytic-uremic syndrome. *N Engl J Med* 368:2169–2181
14. Wong EK, Goodship TH, Kavanagh D (2013) Complement therapy in atypical haemolytic uraemic syndrome (aHUS). *Mol Immunol* 56:199–212
15. Besbas N, Karpman D, Landau D, Loirat C, Proesmans W, Remuzzi G, Rizzoni G, Taylor CM, Van de Kar N, Zimmerhackl LB, Besbas N, Karpman D, Landau D, Loirat C, Proesmans W, Remuzzi G, Rizzoni G, Taylor CM, Van de Kar N, Zimmerhackl LB, European Paediatric Research Group for HUS (2006) A classification of hemolytic uremic syndrome and thrombotic thrombocytopenic purpura and related disorders. *Kidney Int* 70:423–431
16. Loirat C, Frémeaux-Bacchi V (2011) Atypical hemolytic uremic syndrome. *Orphanet J Rare Dis* 6:60
17. Fakhouri F, Jablonski M, Lepercq J, Blouin J, Benachi A, Hourmant M, Pirson Y, Dürrbach A, Grünfeld JP, Knebelmann B, Frémeaux-Bacchi V (2008) Factor H, membrane cofactor protein, and factor I mutations in patients with hemolysis, elevated liver enzymes, and low platelet count syndrome. *Blood* 112:4542–4545
18. Le Quintrec M, Lionet A, Kamar N, Karras A, Barbier S, Buchler M, Fakhouri F, Provost F, Fridman WH, Thervet E, Legendre C, Zuber J, Frémeaux-Bacchi V (2008) Complement mutation-associated de novo thrombotic microangiopathy following kidney transplantation. *Am J Transplant* 8:1694–1701
19. Fakhouri F, Roumenina L, Provot F, Sallée M, Caillard S, Couzi L, Essig M, Ribes D, Dragon-Durey MA, Bridoux F, Rondeau E, Frémeaux-Bacchi V (2010) Pregnancy-associated hemolytic uremic syndrome revisited in the era of complement gene mutations. *J Am Soc Nephrol* 21:859–867
20. Spinale JM, Ruebner RL, Kaplan BS, Copelovitch L (2013) Update on *Streptococcus pneumoniae* associated hemolytic uremic syndrome. *Curr Opin Pediatr* 25:203–208
21. Yagi H, Matsumoto M, Fujimura Y (2012) Paradigm shift of childhood thrombotic thrombocytopenic purpura with severe ADAM TS13 deficiency. *Presse Med* 41:e137–e155
22. Loirat C, Coppo P, Veyradier A (2013) Thrombotic thrombocytopenic purpura in children. *Curr Opin Pediatr* 25:216–224
23. Hassenpflug WA, Budde U, Schneppenheim S, Schneppenheim R (2014) Inherited thrombotic thrombocytopenic purpura in children. *Semin Thromb Hemost* 40:487–492
24. Reese JA, Muthurajah DS, Kremer Hovinga JA, Vesely SK, Terrell DR, George JN (2013) Children and adults with thrombotic thrombocytopenic purpura associated with severe, acquired Adams13 deficiency: comparison of incidence, demographic and clinical features. *Pediatr Blood Cancer* 60:1676–1682
25. Hie M, Gay J, Galicier L, Provôt F, Presne C, Poullin P, Bonmarchand G, Wynckel A, Benhamou Y, Vanhille P, Servais A, Bordessoule D, Coindre JP, Hamidou M, Vernant JP, Veyradier A, Coppo P, French Thrombotic Microangiopathies Reference Centre (2014) Preemptive rituximab infusions after remission efficiently prevent relapses in acquired thrombotic thrombocytopenic purpura. *Blood* 124:204–210
26. Espié E, Grimont F, Mariani-Kurkdjian P, Bouvet P, Haeghebaert S, Filliol I, Loirat C, Decludt B, Minh NN, Vaillant V, de Valk H (2008) Surveillance of hemolytic uremic syndrome in children less than 15 years of age, a system to monitor O157 and non-O157 Shiga toxin-producing *Escherichia coli* infections in France, 1996–2006. *Pediatr Infect Dis J* 27:595–601
27. Rosales A, Hofer J, Zimmerhackl LB, Jungfraithmayr TC, Riedl M, Giner T, Strasak A, Orth-Höller D, Würzner R, Karch H, German-Austrian HUS Study Group (2012) Need for long-term follow-up in enterohemorrhagic *Escherichia coli*-associated hemolytic uremic syndrome due to late-emerging sequelae. *Clin Infect Dis* 54:1413–1421
28. Spinale JM, Ruebner RL, Copelovitch L, Kaplan BS (2013) Long-term outcomes of Shiga toxin hemolytic uremic syndrome. *Pediatr Nephrol* 28:2097–2105
29. Sharma AP, Greenberg CR, Prasad AN, Prasad C (2007) Hemolytic uremic syndrome (HUS) secondary to cobalamin C (cblC) disorder. *Pediatr Nephrol* 22:2097–2103
30. Menni F, Testa S, Guez S, Chiarelli G, Alberti L, Esposito S (2012) Neonatal atypical hemolytic uremic syndrome due to methylmalonic aciduria and homocystinuria. *Pediatr Nephrol* 27:1401–1405
31. Cornec-Le Gall E, Delmas Y, De Parscau L, Doucet L, Ogier H, Benoist JF, Frémeaux-Bacchi V, Le Meur Y (2013) Adult-onset eculizumab-resistant hemolytic uremic syndrome associated with cobalamin C deficiency. *Am J Kidney Dis* 63:119–123
32. Kömhoff M, Roofthoof MT, Westra D, Teertstra TK, Losito A, van de Kar NC, Berger RM (2013) Combined pulmonary hypertension and renal thrombotic microangiopathy in cobalamin C deficiency. *Pediatrics* 132:e540–e544
33. Fischer S, Huemer M, Baumgartner M, Deodato F, Ballhausen D, Boneh A, Burlina AB, Cerone R, Garcia P, Gökçay G, Grünwald S, Häberle J, Jaeken J, Ketteridge D, Lindner M, Mandel H, Martinelli D, Martins EG, Schwab KO, Gruenert SC, Schwahn BC, Sztrihla L, Tomaske M, Trefz F, Vilarinho L, Rosenblatt DS, Fowler B, Dionisi-Vici C (2014) Clinical presentation and outcome in a series of 88 patients with the cblC defect. *J Inher Metab Dis* 37:831–840
34. Huemer M, Scholl-Bürgi S, Hadaya K, Kern I, Beer R, Seppi K, Fowler B, Baumgartner MR, Karall D (2014) Three new cases of late-onset cblC defect and review of the literature illustrating when to consider inborn errors of metabolism beyond infancy. *Orphanet J Rare Dis* 9:161
35. Peffault de Latour R, Xhaard A, Frémeaux-Bacchi V, Coppo P, Fischer AM, Helley D, Socié G (2013) Successful use of



- eculizumab in a patient with post-transplant thrombotic microangiopathy. *Br J Haematol* 161:279–280
36. Jodele S, Licht C, Goebel J, Dixon BP, Zhang K, Sivakumaran TA, Davies SM, Pluthero FG, Lu L, Laskin BL (2013) Abnormalities in the alternative pathway of complement in children with hematopoietic stem cell transplant-associated thrombotic microangiopathy. *Blood* 122:2003–2007
  37. Jodele S, Fukuda T, Vinks A, Mizuno K, Laskin BL, Goebel J, Dixon BP, Teusink A, Pluthero FG, Lu L, Licht C, Davies SM (2014) Eculizumab therapy in children with severe hematopoietic stem cell transplantation-associated thrombotic microangiopathy. *Biol Blood Marrow Transplant* 20:518–525
  38. Szilágyi A, Kiss N, Bereczki C, Tálósi G, Rác K, Túri S, Györke Z, Simon E, Horváth E, Kelen K, Reusz GS, Szabó AJ, Tulassay T, Prohászka Z (2013) The role of complement in *Streptococcus pneumoniae*-associated haemolytic uraemic syndrome. *Nephrol Dial Transplant* 28:2237–2245
  39. Gilbert RD, Nagra A, Haq MR (2013) Does dysregulated complement activation contribute to haemolytic uraemic syndrome secondary to *Streptococcus pneumoniae*? *Med Hypotheses* 81:400–403
  40. Kokame K, Nobe Y, Kokubo Y, Okayama A, Miyata T (2005) FRETS-VWF73, a first fluorogenic substrate for ADAMTS13 assay. *Br J Haematol* 129:93–100
  41. Mackie I, Langley K, Chitolie A, Liesner R, Scully M, Machin S, Peyvandi F (2013) Discrepancies between ADAMTS13 activity assays in patients with thrombotic microangiopathies. *Thromb Haemost* 109:488–496
  42. Thouzeau S, Capdenat S, Stépanian A, Coppo P, Veyradier A (2013) Evaluation of a commercial assay for ADAMTS13 activity measurement. *Thromb Haemost* 110:852–853
  43. Noris M, Bucchioni S, Galbusera M, Donadelli R, Bresin E, Castelletti F, Caprioli J, Brioschi S, Scheiflinger F, Remuzzi G, Noris M, Bucchioni S, Galbusera M, Donadelli R, Bresin E, Castelletti F, Caprioli J, Brioschi S, Scheiflinger F, Remuzzi G, International Registry of Recurrent and Familial HUS/TTP (2005) Complement factor H mutation in familial thrombotic thrombocytopenic purpura with ADAMTS13 deficiency and renal involvement. *J Am Soc Nephrol* 16:1177–1183
  44. Keir LS, Saleem MA (2014) Current evidence for the role of complement in the pathogenesis of Shiga toxin haemolytic uraemic syndrome. *Pediatr Nephrol* 29:1895–1902
  45. Poolpol K, Orth-Höller D, Speth C, Zipfel PF, Skerka C, de Córdoba SR, Brockmeyer J, Bielaszewska M, Würzner R (2014) Interaction of Shiga toxin 2 with complement regulators of the factor H protein family. *Mol Immunol* 58:77–84
  46. Guignon V, Frémeaux-Bacchi V, Giraudier S, Favier R, Borderie D, Massy Z, Mougenot B, Rosenblatt DS, Deschênes G (2005) Late-onset thrombotic microangiopathy caused by cblC disease: association with a factor H mutation. *Am J Kidney Dis* 45:588–595
  47. Bouts AH, Roofthoof MT, Salomons GS (2010) CD46-associated atypical hemolytic uremic syndrome with uncommon course caused by cblC deficiency. *Pediatr Nephrol* 25:2547–2548
  48. Loirat C, Saland J, Bitzan M (2012) Management of hemolytic uremic syndrome. *Presse Med* 41:e115–e135
  49. Ståhl AL, Vaziri-Sani F, Heinen S, Kristofferson AC, Gydell KH, Raafat R, Gutierrez A, Beringer O, Zipfel PF, Karpman D (2008) Factor H dysfunction in patients with atypical hemolytic uremic syndrome contributes to complement deposition on platelets and their activation. *Blood* 111:5307–5315
  50. Dragon-Durey MA, Sethi SK, Bagga A, Blanc C, Blouin J, Ranchin B, André JL, Takagi N, Cheong HI, Hari P, Le Quintrec M, Niaudet P, Loirat C, Fridman WH, Frémeaux-Bacchi V (2010) Clinical features of anti-factor H autoantibody-associated hemolytic uremic syndrome. *J Am Soc Nephrol* 21:2180–2187
  51. Hofer J, Janecke AR, Zimmerhackl LB, Riedl M, Rosales A, Giner T, Cortina G, Haindl CJ, Petzelberger B, Pawlik M, Jeller V, Vester U, Gadner B, van Husen M, Moritz ML, Würzner R, Jungtraithmayr T, German-Austrian HUS Study Group (2013) Complement factor H-related protein 1 deficiency and factor H antibodies in pediatric patients with atypical hemolytic uremic syndrome. *Clin J Am Soc Nephrol* 8:407–415
  52. Sinha A, Gulati A, Saini S, Blanc C, Gupta A, Gurjar BS, Saini H, Kotresh ST, Ali U, Bhatia D, Ohri A, Kumar M, Agarwal I, Gulati S, Anand K, Vijayakumar M, Sinha R, Sethi S, Salmona M, George A, Bal V, Singh G, Dinda AK, Hari P, Rath S, Dragon-Durey MA, Bagga A (2014) Prompt plasma exchanges and immunosuppressive treatment improves the outcomes of anti-factor H autoantibody-associated hemolytic uremic syndrome in children. *Kidney Int* 85:1151–1160
  53. Loirat C, Frémeaux-Bacchi V (2014) Anti-factor H autoantibody-associated hemolytic uremic syndrome: the earlier diagnosed and treated, the better. *Kidney Int* 85:1019–1022
  54. Hofer J, Giner T, Józsi M (2014) Complement factor h-antibody-associated hemolytic uremic syndrome: pathogenesis, clinical presentation, and treatment. *Semin Thromb Hemost* 40:431–443
  55. Malina M, Gulati A, Bagga A, Majid MA, Simkova E, Schaefer F (2013) Peripheral gangrene in children with atypical hemolytic uremic syndrome. *Pediatrics* 131:e331–e335
  56. Westland R, Bodria M, Carrea A, Lata S, Scolari F, Frémeaux-Bacchi V, D'Agati VD, Lifton RP, Gharavi AG, Ghiggeri GM, Sanna-Cherchi S (2014) Phenotypic expansion of DGKE-associated diseases. *J Am Soc Nephrol* 25:1408–1414
  57. Sánchez Chinchilla D, Pinto S, Hoppe B, Adragna M, Lopez L, Justa Roldan ML, Peña A, Lopez Trascasa M, Sánchez-Corral P, Rodríguez de Córdoba S (2014) Complement mutations in diacylglycerol kinase-ε-associated atypical hemolytic uremic syndrome. *Clin J Am Soc Nephrol* 9:1611–1619
  58. Frémeaux-Bacchi V, Moulton EA, Kavanagh D, Dragon-Durey MA, Blouin J, Caudy A, Arzouk N, Cleper R, Francois M, Guest G, Pourrat J, Seligman R, Fridman WH, Loirat C, Atkinson JP (2006) Genetic and functional analyses of membrane cofactor protein (CD46) mutations in atypical hemolytic uremic syndrome. *J Am Soc Nephrol* 17:2017–2025
  59. Bresin E, Rurali E, Caprioli J, Sanchez-Corral P, Frémeaux-Bacchi V, Rodríguez de Córdoba S, Pinto S, Goodship TH, Alberti M, Ribes D, Valoti E, Remuzzi G, Noris M, European Working Party on Complement Genetics in Renal Diseases (2013) Combined complement gene mutations in atypical hemolytic uremic syndrome influence clinical phenotype. *J Am Soc Nephrol* 24:475–486
  60. Bu F, Maga T, Meyer NC, Wang K, Thomas CP, Nester CM, Smith RJ (2014) Comprehensive genetic analysis of complement and coagulation genes in atypical hemolytic uremic syndrome. *J Am Soc Nephrol* 25:55–64
  61. Feng S, Eyler SJ, Zhang Y, Maga T, Nester CM, Kroll MH, Smith RJ, Afshar-Kharghan V (2013) Partial ADAMTS13 deficiency in atypical hemolytic uremic syndrome. *Blood* 122:1487–1493
  62. Moore I, Strain L, Pappworth I, Kavanagh D, Barlow PN, Herbert AP, Schmidt CQ, Staniforth SJ, Holmes LV, Ward R, Morgan L, Goodship TH, Marchbank KJ (2010) Association of factor H autoantibodies with deletions of CFHR1, CFHR3, CFHR4, and with mutations in CFH, CFI, CD46, and C3 in patients with atypical hemolytic uremic syndrome. *Blood* 115:379–387
  63. Holmes LV, Strain L, Staniforth SJ, Moore I, Marchbank K, Kavanagh D, Goodship JA, Cordell HJ, Goodship TH (2013) Determining the population frequency of the CFHR3/CFHR1 deletion at 1q32. *PLoS One* 8:e60352
  64. Quaggin SE (2013) DGKE and atypical HUS. *Nat Genet* 45:475–476
  65. Geerdink LM, Westra D, van Wijk JA, Dorresteyn EM, Lilien MR, Davin JC, Kömhoff M, Van Hoeck K, van der Vlugt A, van den Heuvel LP, van de Kar NC (2012) Atypical hemolytic uremic

- syndrome in children: complement mutations and clinical characteristics. *Pediatr Nephrol* 27:1283–1291
66. Cataland SR, Holers VM, Geyer S, Yang S, Wu HM (2014) Biomarkers of the alternative pathway and terminal complement activity at presentation confirms the clinical diagnosis of aHUS and differentiates aHUS from TTP. *Blood* 123:3733–3738
67. Noris M, Galbusera M, Gastoldi S, Macor P, Banterla F, Bresin E, Tripodo C, Bettoni S, Donadelli R, Valoti E, Tedesco F, Amore A, Coppo R, Ruggenenti P, Gotti E, Remuzzi G (2014) Dynamics of complement activation in aHUS and how to monitor eculizumab therapy. *Blood* 124:1715–1726
68. Volokhina EB, Westra D, van der Velden TJ, van de Kar NC, Mollnes TE, van den Heuvel LP (2014) Complement activation patterns in atypical hemolytic uremic syndrome during acute phase and in remission. *Clin Exp Immunol*. doi:10.1111/cei.12426
69. Watson R, Lindner S, Bordereau P, Hunze EM, Tak F, Ngo S, Zipfel PF, Skerka C, Dragon-Durey MA, Marchbank KJ (2014) Standardisation of the factor H autoantibody assay. *Immunobiology* 219:9–16
70. Le Quintrec M, Zuber J, Moulin B, Kamar N, Jablonski M, Lionet A, Chatelet V, Mousson C, Mourad G, Bridoux F, Cassuto E, Loirat C, Rondeau E, Delahousse M, Frémeaux-Bacchi V (2013) Complement genes strongly predict recurrence and graft outcome in adult renal transplant recipients with atypical hemolytic and uremic syndrome. *Am J Transplant* 13:663–675
71. Zuber J, Le Quintrec M, Krid S, Bertoye C, Gueutin V, Lahoche A, Heyne N, Ardissino G, Chatelet V, Noël LH, Hourmant M, Niaudet P, Frémeaux-Bacchi V, Rondeau E, Legendre C, Loirat C, French Study Group for Atypical HUS (2012) Eculizumab for atypical hemolytic uremic syndrome recurrence in renal transplantation. *Am J Transplant* 12:3337–3354
72. Khandelwal P, Sinha A, Hari P, Bansal VK, Dinda AK, Bagga A (2014) Outcomes of renal transplant in patients with anti-complement factor H antibody-associated hemolytic uremic syndrome. *Pediatr Transplant* 18:E134–E139
73. Sinibaldi S, Guzzo I, Piras R, Bresin E, Emma F, Dello Strologo L (2013) Post-transplant recurrence of atypical hemolytic uremic syndrome in a patient with thrombomodulin mutation. *Pediatr Transplant* 17:E177–E181
74. Saland JM, Ruggenenti P, Remuzzi G, Consensus Study Group (2009) Liver–kidney transplantation to cure atypical hemolytic uremic syndrome. *J Am Soc Nephrol* 20:940–949
75. European Medicines Agency. Soliris (eculizumab): EU summary of product characteristics. Mar14 [http://www.emea.europa.eu/docs/en\\_GB/document\\_library/EPAR\\_Product\\_Information/human/000791/WC500054208.pdf](http://www.emea.europa.eu/docs/en_GB/document_library/EPAR_Product_Information/human/000791/WC500054208.pdf)
76. Alexion Pharmaceuticals Inc. Soliris (eculizumab): US prescribing information. 4/2014. [http://www.accessdata.fda.gov/drugsatfda\\_docs/label/2014/125166s368s380lbl.pdf](http://www.accessdata.fda.gov/drugsatfda_docs/label/2014/125166s368s380lbl.pdf)
77. Licht C, Greenbaum LA, Muus P, Babu S, Bedrosian CL, Cohen D, Delmas Y, Douglas K, Furman R, Gaber O, Goodship T, Herthelius M, Hourmant M, Legendre C, Remuzzi G, Sheerin N, Trivelli A, Loirat C (2015) Efficacy and safety of eculizumab in atypical hemolytic uremic syndrome: 2-year results from extensions of phase 2 studies. *Kidney Int*. doi:10.1038/ki.2014.423
78. Legendre C, Greenbaum L, Sheerin N, Cohen D, Gaber A, Eitner F, Delmas Y, Furman R, Feldkamp T, Fouque D, Bedrosian C, Loirat C (2013) Eculizumab efficacy in aHUS patients with progressing TMA, with or without prior renal transplant [Abstract]. *Am J Transplant* 13:278–279
79. Greenbaum LA, Fila M, Tsimaratos M, Ardissino G, Al-Akash SI, Evans J, Henning P, Lieberman KV, Maringhini S, Pape L, Rees L, Van De Kar N, Van De Walle J, Ogawa M, Bedrosian CL, Licht C (2013) Eculizumab inhibits thrombotic microangiopathy and improves renal function in pediatric atypical hemolytic uremic syndrome patients [Abstract]. *J Am Soc Nephrol* 24:821A–822A
80. Fakhouri F, Hourmant M, Campistol Plana JM, Cataland SR, Espinosa M, Gaber AO, Menne J, Minetti EE, Provot F, Rondeau E, Ruggenenti PL, Weekers LE, Ogawa M, Bedrosian CL, Legendre CM (2014) Eculizumab inhibits thrombotic microangiopathy, and improves renal function in adult atypical hemolytic uremic syndrome patients: 1-Year Update [Abstract]. *J Am Soc Nephrol* 25:751A
81. Loirat C, Legendre CM, Ogawa M, Bedrosian CL, Kincaid J, Fakhouri F (2014) Safety and efficacy of eculizumab in adult aHUS patients, with or without a history of renal transplant [Abstract]. *J Am Soc Nephrol* 25:754
82. Rathbone J, Kaltenthaler E, Richards A, Tappenden P, Bessey A, Cantrell A (2013) A systematic review of eculizumab for atypical haemolytic uraemic syndrome (aHUS). *BMJ Open* 3:e003573
83. Vilalta R, Lara E, Madrid A, Chocron S, Muñoz M, Casquero A, Nieto J (2012) Long-term eculizumab improves clinical outcomes in atypical hemolytic uremic syndrome. *Pediatr Nephrol* 27:2323–2326
84. Cayci FS, Cakar N, Hancer VS, Uncu N, Acar B, Gur G (2012) Eculizumab therapy in a child with hemolytic uremic syndrome and CFI mutation. *Pediatr Nephrol* 27:2327–2331
85. Giordano M, Castellano G, Messina G, Divella C, Bellantuono R, Puteo F, Colella V, Depalo T, Gesualdo L (2012) Preservation of renal function in atypical hemolytic uremic syndrome by eculizumab: a case report. *Pediatrics* 130:e1385–e1388
86. Besbas N, Gulhan B, Karpman D, Topaloglu R, Duzova A, Korkmaz E, Ozaltin F (2013) Neonatal onset atypical hemolytic uremic syndrome successfully treated with eculizumab. *Pediatr Nephrol* 28:155–158
87. Gulleroglu K, Fidan K, Hançer VS, Bayrakci U, Baskin E, Soylemezoglu O (2013) Neurologic involvement in atypical hemolytic uremic syndrome and successful treatment with eculizumab. *Pediatr Nephrol* 28:827–830
88. Gilbert RD, Fowler DJ, Angus E, Hardy SA, Stanley L, Goodship TH (2013) Eculizumab therapy for atypical haemolytic uraemic syndrome due to a gain-of-function mutation of complement factor B. *Pediatr Nephrol* 28:1315–1318
89. Vaisbich MH, Henriques Ldos S, Watanabe A, Pereira LM, Metran CC, Malheiros DA, Modanez F, Silva JD, Vieira S, Macedo AC, Massaro B, Furusawa EA, Schvartsman BG (2013) Eculizumab for the treatment of atypical hemolytic uremic syndrome: case report and revision of the literature. *J Bras Nefrol* 35:237–241
90. Hu H, Nagra A, Haq MR, Gilbert RD (2013) Eculizumab in atypical haemolytic uraemic syndrome with severe cardiac and neurological involvement. *Pediatr Nephrol* 29:1103–1106
91. Christmann M, Hansen M, Bergmann C, Schwabe D, Brand J, Schneider W (2014) Eculizumab as first-line therapy for atypical hemolytic uremic syndrome. *Pediatrics* 133:e1759–e1763
92. Michaux K, Bacchetta J, Javouhey E, Cochat P, Frémeaux-Bacchi V, Sellier-Leclerc AL (2014) Eculizumab in neonatal hemolytic uremic syndrome with homozygous factor H deficiency. *Pediatr Nephrol* 29:2415–2419
93. Fakhouri F, Delmas Y, Provot F, Barbet C, Karras A, Makdassi R, Courivaud C, Rifard K, Servais A, Allard C, Besson V, Cousin M, Châtelet V, Goujon JM, Coindre JP, Laurent G, Loirat C, Frémeaux-Bacchi V (2014) Insights from the use in clinical practice of eculizumab in adult patients with atypical hemolytic uremic syndrome affecting the native kidneys: an analysis of 19 cases. *Am J Kidney Dis* 63:40–48
94. Hodgkins KS, Bobrowski AE, Lane JC, Langman CB (2012) Clinical grand rounds: atypical hemolytic uremic syndrome. *Am J Nephrol* 35:394–394
95. Alachkar N, Bagnasco SM, Montgomery RA (2012) Eculizumab for the treatment of two recurrences of atypical hemolytic uremic syndrome in a kidney allograft. *Transpl Int* 25:e93–e95



96. Reuter S, Heitplatz B, Pavenstädt H, Suwelack B (2013) Successful long-term treatment of TMA with eculizumab in a transplanted patient with atypical hemolytic uremic syndrome due to MCP mutation. *Transplantation* 96:e74–e76
97. Zuber J, Le Quintrec M, Morris H, Frémeaux-Bacchi V, Loirat C, Legendre C (2013) Targeted strategies in the prevention and management of atypical HUS recurrence after kidney transplantation. *Transplant Rev (Orlando)* 27:117–125
98. Xie L, Nester CM, Reed AI, Zhang Y, Smith RJ, Thomas CP (2012) Tailored eculizumab therapy in the management of complement factor H-mediated atypical hemolytic uremic syndrome in an adult kidney transplant recipient: a case report. *Transplant Proc* 44:3037–3040
99. Pelicano MB, de Córdoba SR, Diekmann F, Saiz M, Herrero S, Oppenheimer F, Campistol JM (2013) Anti-C5 as prophylactic therapy in atypical hemolytic uremic syndrome in living-related kidney transplantation. *Transplantation* 96:e26–e29
100. Román-Ortiz E, Mendizabal Oteiza S, Pinto S, López-Trascasa M, Sánchez-Corral P, Rodríguez de Córdoba S (2014) Eculizumab long-term therapy for pediatric renal transplant in aHUS with CFH/CFHR1 hybrid gene. *Pediatr Nephrol* 29:149–153
101. Békássy ZD, Kristoffersson AC, Cronqvist M, Roumenina LT, Rybkine T, Vergoz L, Hue C, Frémeaux-Bacchi V, Karpman D (2013) Eculizumab in an anephric patient with atypical haemolytic uraemic syndrome and advanced vascular lesions. *Nephrol Dial Transplant* 28:2899–2907
102. Walport MJ (2001) Complement. First of two parts. *N Engl J Med* 344:1058–1066
103. Nolan TM, Nissen MD, Naz A, Shepard J, Bedell L, Hohenboken M, Odrlijn T, Dull PM (2013) Immunogenicity and safety of a CRM-conjugated meningococcal ACWY vaccine administered concomitantly with routine vaccines starting at 2 months of age. *Hum Vaccin Immunother* 10:280–289
104. Abdelnour A, Silas PE, Lamas MR, Aragón CF, Chiu NC, Chiu CH, Acuña TH, Castrejón Tde L, Izu A, Odrlijn T, Smolenov I, Hohenboken M, Dull PM (2014) Safety of a quadrivalent meningococcal serogroups A, C, W and Y conjugate vaccine (MenACWY-CRM) administered with routine infant vaccinations: results of an open-label, randomized, phase 3b controlled study in healthy infants. *Vaccine* 32:965–972
105. Zlomy M, Hofer J, Elias J, Vogel U, Frosch M, Jungrathmayr T, Zimmerhackl LB, Prelog M (2012) Immunogenicity of meningococcus C vaccination in a patient with atypical hemolytic uremic syndrome (aHUS) on eculizumab therapy. *Pediatr Transplant* 16:E246–E250
106. Struijk GH, Bouts AH, Rijkers GT, Kuin EA, ten Berge IJ, Bemelman FJ (2013) Meningococcal sepsis complicating eculizumab treatment despite prior vaccination. *Am J Transplant* 13:819–820
107. Hillmen P, Muus P, Röth A, Elebute MO, Risitano AM, Schrezenmeier H, Szer J, Browne P, Maciejewski JP, Schubert J, Urbano-Ispizua A, de Castro C, Socié G, Brodsky RA (2013) Long-term safety and efficacy of sustained eculizumab treatment in patients with paroxysmal nocturnal haemoglobinuria. *Br J Haematol* 162:62–73
108. Sana G, Dragon-Durey MA, Charbit M, Bouchireb K, Rousset-Rouvière C, Bérard E, Salomon R, Frémeaux-Bacchi V, Niaudet P, Boyer O (2014) Long-term remission of atypical HUS with anti-factor H antibodies after cyclophosphamide pulses. *Pediatr Nephrol* 29:75–83
109. Noone D, Waters A, Pluthero FG, Geary DF, Kirschfink M, Zipfel PF, Licht C (2014) Successful treatment of DEAP-HUS with eculizumab. *Pediatr Nephrol* 29:841–851
110. Diamante Chiodini B, Davin JC, Corazza F, Khaldi K, Dahan K, Ismaili K, Adams B (2014) Eculizumab in anti-factor h antibodies associated with atypical hemolytic uremic syndrome. *Pediatrics* 133:e1764–e1768
111. Green H, Harari E, Davidovits M, Blickstein D, Grossman A, Gafer U, Gafer-Gvili A (2014) Atypical HUS due to factor H antibodies in an adult patient successfully treated with eculizumab. *Ren Fail* 36:1119–1121
112. Sellier-Leclerc AL, Frémeaux-Bacchi V, Dragon-Durey MA, Macher MA, Niaudet P, Guest G, Boudailliez B, Bouissou F, Deschenes G, Gie S, Tsimaratos M, Fischbach M, Morin D, Nivet H, Alberti C, Loirat C, French Society of Pediatric Nephrology (2007) Differential impact of complement mutations on clinical characteristics in atypical hemolytic uremic syndrome. *J Am Soc Nephrol* 18:2392–2400
113. Réti M, Farkas P, Csuka D, Rázsó K, Schlammadinger Á, Udvardy ML, Madách K, Domján G, Bereczki C, Reusz GS, Szabó AJ, Prohászka Z (2012) Complement activation in thrombotic thrombocytopenic purpura. *J Thromb Haemost* 10:791–798
114. Noris M, Mescia F, Remuzzi G (2012) STEC-HUS, atypical HUS and TTP are all diseases of complement activation. *Nat Rev Nephrol* 8:622–633
115. Wu TC, Yang S, Haven S, Holers VM, Lundberg AS, Wu H, Cataland SR (2013) Complement activation and mortality during an acute episode of thrombotic thrombocytopenic purpura. *J Thromb Haemost* 11:1925–1927
116. Westwood JP, Langley K, Heelas E, Machin SJ, Scully M (2014) Complement and cytokine response in acute Thrombotic Thrombocytopenic Purpura. *Br J Haematol* 164:858–856
117. Tati R, Kristoffersson AC, Ståhl AL, Rebetz J, Wang L, Licht C, Motto D, Karpman D (2013) Complement activation associated with ADAMTS13 deficiency in human and murine thrombotic microangiopathy. *J Immunol* 191:2184–2193
118. Chapin J, Weksler B, Magro C, Laurence J (2012) Eculizumab in the treatment of refractory idiopathic thrombotic thrombocytopenic purpura. *Br J Haematol* 157:772–774
119. Tsai E, Chapin J, Laurence JC, Tsai HM (2013) Use of eculizumab in the treatment of a case of refractory, ADAMTS13-deficient thrombotic thrombocytopenic purpura: additional data and clinical follow-up. *Br J Haematol* 162:558–559
120. Belingheri M, Possenti I, Tel F, Paglialonga F, Testa S, Salardi S, Ardissino G (2014) Cryptic activity of atypical hemolytic uremic syndrome and eculizumab treatment. *Pediatrics* 133:e1769–e1771
121. Ariceta G, Arrizabalaga B, Aguirre M, Morteruel E, Lopez-Trascasa M (2012) Eculizumab in the treatment of atypical hemolytic uremic syndrome in infants. *Am J Kidney Dis* 59:707–710
122. Ardissino G, Tel F, Testa S, Marzano AV, Lazzari R, Salardi S, Edefonti A (2013) Skin involvement in atypical hemolytic uremic syndrome. *Am J Kidney Dis* 63:652–655
123. Ohanian M, Cable C, Halka K (2011) Eculizumab safely reverses neurologic impairment and eliminates need for dialysis in severe atypical hemolytic uremic syndrome. *Clin Pharmacol* 3:5–12
124. Salem G, Flynn JM, Cataland SR (2013) Profound neurological injury in a patient with atypical hemolytic uremic syndrome. *Ann Hematol* 92:557–558
125. Beye F, Malbranche C, Tramecon D, Pernot C, Zanetta G, Mousson C, Guignard MH, Lazzarotti A (2013) Eculizumab: effectiveness of a shortened dosing schedule in the treatment of atypical haemolytic uremic syndrome of unknown origin. *Thérapie* 68:119–122
126. Pu JJ, Sido A (2014) Successful discontinuation of eculizumab therapy in a patient with aHUS. *Ann Hematol* 93:1423–1425
127. Chaudhary P, Hepgur M, Sarkissian S, Smith RJ, Weitz IC (2014) Atypical haemolytic-uraemic syndrome due to heterozygous mutations of CFH/CFHR1-3 and complement factor H 479. *Blood Transfus* 12:111–113
128. Loirat C, Macher MA, Elmaleh-Berges M, Kwon T, Deschênes G, Goodship TH, Majoie C, Davin JC, Blanc R, Savatovsky J, Moret J, Frémeaux-Bacchi V (2010) Non-atheromatous arterial stenoses in

- atypical haemolytic uraemic syndrome associated with complement dysregulation. *Nephrol Dial Transplant* 25:3421–3425
129. Davin JC, Majoie C, Groothoff J, Gracchi V, Bouts A, Goodship TH, Loirat C (2011) Prevention of large-vessel stenoses in atypical hemolytic uremic syndrome associated with complement dysregulation. *Pediatr Nephrol* 26:155–157
130. Ažukaitis K, Loirat C, Malina M, Adomaitienė I, Jankauskienė A (2013) Macrovascular involvement in a child with atypical hemolytic uremic syndrome. *Pediatr Nephrol* 29:1273–1277
131. Gargau M, Azancot M, Ramos R, Sanchez-Corral P, Montero MA, Seron D (2012) Early treatment with eculizumab may be beneficial in atypical haemolytic uraemic syndrome. *Clin Kidney J* 5:1–3
132. Kim JJ, Simon CW, Reid CJ (2012) Eculizumab in atypical haemolytic-uraemic syndrome allows cessation of plasma exchange and dialysis. *Clin Kidney J* 0:1–3
133. Povey H, Vundru R, Junglee N, Jibani M (2013) Renal recovery with eculizumab in atypical hemolytic uremic syndrome following prolonged dialysis. *Clin Nephrol* 82:326–331
134. Noris M, Remuzzi G (2014) Cardiovascular complications in atypical haemolytic uraemic syndrome. *Nat Rev Nephrol* 10:174–180
135. Nishimura J, Yamamoto M, Hayashi S, Ohyashiki K, Ando K, Brodsky AL, Noji H, Kitamura K, Eto T, Takahashi T, Masuko M, Matsumoto T, Wano Y, Shichishima T, Shibayama H, Hase M, Li L, Johnson K, Lazarowski A, Tamburini P, Inazawa J, Kinoshita T, Kanakura Y (2014) Genetic variants in C5 and poor response to eculizumab. *N Engl J Med* 370:632–639
136. Cugno M, Gualtierotti R, Possenti I, Testa S, Tel F, Griffini S, Grovetti E, Tedeschi S, Salardi S, Cresseri D, Messa P, Ardissino G (2014) Complement functional tests for monitoring eculizumab treatment in patients with atypical hemolytic uremic syndrome. *J Thromb Haemost* 12:1440–1448
137. Mache CJ, Acham-Roschitz B, Frémeaux-Bacchi V, Kirschfink M, Zipfel PF, Roedel S, Vester U, Ring E (2009) Complement inhibitor eculizumab in atypical hemolytic uremic syndrome. *Clin J Am Soc Nephrol* 4:1312–1316
138. Köse O, Zimmerhackl LB, Jungtraithmayr T, Mache C, Nürnberger J (2010) New treatment options for atypical hemolytic uremic syndrome with the complement inhibitor eculizumab. *Semin Thromb Hemost* 36:669–672
139. Carr R, Cataland SR (2013) Relapse of aHUS after discontinuation of therapy with eculizumab in a patient with aHUS and factor H mutation. *Ann Hematol* 92:845–846
140. Delmas Y, Bordes C, Loirat C, Frémeaux-Bacchi V, Combe C (2013) Post-partum atypical haemolytic uraemic syndrome treated with eculizumab: terminal complement activity assessment in clinical practice. *Clin Kidney J* 6:243–244
141. Cañigral C, Moscardó F, Castro C, Pajares A, Lancharro A, Solves P, de la Rubia J, Carpio N, Sanz MA (2014) Eculizumab for the treatment of pregnancy-related atypical hemolytic uremic syndrome. *Ann Hematol* 93:1421–1422
142. Ardissino G, Testa S, Possenti I, Tel F, Paglialonga F, Salardi S, Tedeschi S, Belingheri M, Cugno M (2014) Discontinuation of eculizumab maintenance treatment for atypical hemolytic uremic syndrome: a report of 10 cases. *Am J Kidney Dis* 64:633–637
143. Verhave JC, Westra D, van Hamersvelt HW, van Helden M, van de Kar NC, Wetzels JF (2013) Living kidney transplantation in adult patients with atypical haemolytic uraemic syndrome. *Neth J Med* 71:342–347
144. Forbes TA, Bradbury MG, Goodship TH, McKiernan PJ, Milford DV (2013) Changing strategies for organ transplantation in atypical haemolytic uraemic syndrome: a tertiary case series. *Pediatr Transplant* 17:E93–E99
145. Saland J (2014) Liver–kidney transplantation to cure atypical HUS: still an option post-eculizumab? *Pediatr Nephrol* 29:329–332
146. Park SH, Kim GS (2014) Anesthetic management of living donor liver transplantation for complement factor H deficiency hemolytic uremic syndrome: a case report. *Korean J Anesthesiol* 66:481–485